

Evaluation of Smile Components in Males of Skeletal Class III compared to Skeletal Class I

Abdallah S Nouh^{1*}, HM Abdel Majeed² and Essam Mohamed Nassef Selim²

¹Atomic Energy Authority, Nasr City, Cairo, Egypt

²Department of Orthodontics, Faculty of Oral and Dental Medicine, Future University, Cairo, Egypt

*Corresponding Author: Abdallah S Nouh, Atomic Energy Authority, Nasr City, Cairo, Egypt.

Received: September 26, 2021; Published: October 01, 2021

Abstract

Objective: Smile plays a vital role in facial appearance. The current study was performed to evaluate the smile parameter variations between Class I and Class III male subjects aiming to obtain a full understanding to smile features serving in diagnosis and treatment planning for highest patient satisfaction.

Materials and Methods: This study was performed on 30 skeletal Class III and Class I males. Two frontal digital photographs were taken for each subject, one at rest and the other in the posed smile position. Photographs were uploaded on Photoshop software for standardization and then uploaded on the Digital Smile Design software (DSD) where the actual incisogingival height of the central incisor was used for automatic calibration.

Results: At rest, there was no significant difference for all soft tissue measurements of Class I and Class III males, while on smiling, Class III males tended to have wider smile widths, less incisor display, wider smile width and a higher percentage of non-consonant and flat smile arcs than normal Class I subjects.

Conclusions: The maxillary incisor display for Class I was found to be significantly greater than that for Class III. The smile width and smile height for Class III was found to be significantly greater than that of Class I.

Keywords: Class III males; Esthetics; Malocclusion; Smile

Introduction

The importance of beauty and attractiveness in today's society has been well established. Physically attractive people are perceived to be more kind, sensitive, sociable and responsive. It is also believed that attractive people are more likely to obtain better jobs, experience happier and more fulfilling lives. These societal biases begin early in life and impact a person's future for a lifetime. Dentofacial attractiveness is particularly important to a person's psychosocial well being, where people with a normal dental appearance are judged more socially attractive over many personal characteristics than those with malocclusions. Those with poor dental esthetics have been linked to lack of self-confidence and are thought to be disadvantaged in social, educational, and occupational settings [1].

A smile is a facial expression that is globally known as a sign of happiness, a means of communication, and an important factor influencing esthetics and attractiveness of the face. A smile is an outward sign of perceived self-confidence and internal satisfaction. It has been shown that smiling and other such expressions of positive emotions are important to shaping relationships with others. In the past there have been different criteria for smile analysis and design. Earlier, the clinical examination and diagnosis in treatment planning were largely focused on dental, and skeletal hard tissue elements involved in a patient. The reemergence of the soft tissue paradigm in orthodontics has shifted diagnostic thinking to focus on soft tissue hard tissue interrelation and how they contribute to the overall facial aesthetic make-up of the patient [2].

Orthodontic diagnosis has come a long way and now includes patient-driven esthetic diagnosis and treatment planning along with its problem oriented approach. Analyzing the smile and obtaining averages for various smile components gives an idea about a standard of normalcy to serve as a guideline for the creation of an esthetic smile [3].

Several health professionals including orthodontists try their best to improve the attractiveness of the patients' smile. Thus, smile analysis has always been of interest to orthodontists and has recently become a key element of almost all orthodontic treatment plans [4]. Tosun and Kaya [5] studied the effect of maxillary incisors, lower lip, and gingival display relationship on smile beauty in male subjects. They investigated that the esthetic smile needs the interaction of different parameters. Assessment and enhancement of those parameters are essential for orthodontists since smile beauty is the parameter considered by nearly all patients to evaluate the achievement of orthodontic treatment [6]. Godinho *et al.* [7] studied the donation of facial components to the beauty of the smile in patients. They found that the malocclusions affect the attractiveness, intelligence and character. Persons with a regular occlusion are more attractive, intelligent, pleasant and demonstrative. Additionally, a study of the influence of teeth arrangement on human personality indicated that people with ideal smiles were smarter and more appropriate for the job [8].

Nonsurgical treatment of Class III troubles remains a challenge in our occupation. However, rapid diagnosis and early intervention of Class III malocclusion can be helpful to decrease the amount of burden for severe Class III malocclusion in late adolescence [9, 10].

Since patients became more worried about the esthetics of their smile, it is more applicable for orthodontists to take care to the soft tissue framework. It would be careful to assess the factors of a smile before treatment to find out the requirements to be done and the communications with the patient and parent [11, 12]. The present study aims to evaluate the smile parameter characteristics in males of skeletal Class III compared to skeletal Class I, for orthodontic diagnosis and proper treatment planning to reach the maximum patient satisfaction.

Materials and Methods

The current study was performed on 30 skeletal Class III and Class I male subjects with average vertical facial patterns. In a previous study by Kakadiya *et al.* [13] the response within skeletal Class I and III groups was normally distributed true difference between the study groups was 1.42.

Sample size calculation indicated that for a study with a power of 80% and an α error of 0.05, the minimum estimated sample size was 9 cases per group for a total of 18 cases. 30 males were included in the present study, according to the skeletal discrepancy whether mandibular excess or maxillary deficiency, divided into two groups which included 15 males for each group. Subjects included in the study had an average age of 18-30 years in order to minimize the effects of growth on facial appearance as reported by Leonardi *et al.* [14] whereas those with congenitally missing, malformed or extracted teeth, having fixed bridges or crowns visible on smiling, excessive dental attrition, lip irregularity or history of lip surgery and facial asymmetries were excluded from the study. Two frontal photographs at rest and subjects' commissure to commissure posed smile were taken by a Canon G11 camera set on a tripod from a fixed distance of 1.5 m where the camera was focused on the mouth showing from the nose to the chin. The camera lens was adjusted to be parallel to the floor by adjusting the mount head of the tripod guided by the leveling indicator that is built in the tripod. Photographs were taken for each patient in the natural head position. The head was held in an upright posture and eyes were focused on a point in the distance at eye level such that the visual axis was horizontal. For measuring smile variables the DSD software program was used. Standardization was mandatory to avoid any magnification errors where the incisogingival height of the right and left maxillary central incisors, lateral incisor and the canine were clinically measured (actual height) for each case using a vernier caliper to the nearest 0.1 mm found to be the same. Photographs were uploaded on Photoshop software for standardization and a reading for the incisogingival height of the right maxillary central incisor was done where a ratio of 7:5, as reported by Nouh AS *et al.* [15] Provides the most accurate image guided by the actual clinical height of the central incisor. The new standardized photos were uploaded on the DSD software to be calibrated to measure all linear variables in to the nearest 0.1 mm. The actual incisogingival height in millimeters was used for automatic calibration by the digital smile system (DSS) where twelve smile components were evaluated at rest and on smiling.

Figure 1 shows the (1) Upper lip length which is the distance between the base of the nose (Subnasale) and the inferior part of the upper lip (Stomion superius) (Stom_s), (2) Upper lip thickness which is the vertical distance from the most superior point of the cupid's bow to the most inferior portion of the tubercle of the lower lip. (3) Intercommissure width which is the horizontal distance between two parallel lines extending vertically from the corners of the mouth, (4) Lower facial height which is the vertical distance between Subnasale (Sn) to soft tissue Menton (Me'), (5) Lower lip thickness which is the vertical distance between Stomion (Stom) to Labrale inferius (Li), (6) Lower lip length which is the vertical distance from Stomion (Stom) to Sulcus inferius (Si). And (7) Chin height which is the vertical distance from Sulcus inferius (Si) to soft tissue Gnathion (Gn').

Figure 2 shows the (8) Smile width which is the horizontal distance between the left outer commissure to the right outer commissure of the lips on smiling, (9) Maxillary Incisor display which is the amount of vertical tooth exposure during smiling, (10) Buccal corridor which is the distance between the most distal maxillary dentition and the commissure, (11) Gingival display which is the amount of maxillary gingival exposure between inferior border of upper lip and marginal gingiva of maxillary central incisors in mm and (12) Smile arc which is the relationship of the curvature of the incisal edges of the maxillary incisors and canines to the curvature of the lower lip in the posed smile.

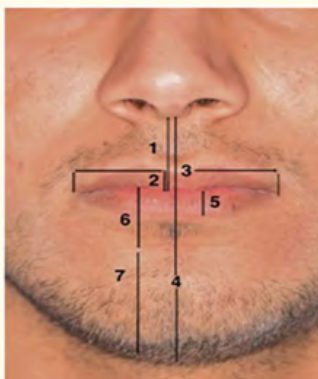


Figure 1: (1) Upper lip length, (2) Upper lip thickness, (3) Intercommissure width, (4) Lower facial height, (5) Lower lip thickness, (6) Lower lip length and (7) Chin height.

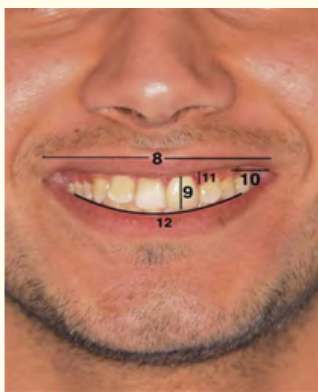


Figure 2: (8) Smile width, (9) Incisor display, (10) Buccal corridor, (11) Gingival display and (12) Smile arc.

Statistical analysis

Numerical data were illustrated for normality by checking the distribution of data and through tests of normality (Kolmogorov–Smirnov and Shapiro–Wilk tests). All data showed normal (parametric) distribution except for the gingival display which showed nonnormal (nonparametric) distribution. Data are presented as means, standard deviation (SD), mean difference and 95% confidence interval (95% CI) for the difference values. For parametric data, Student’s *t* test was used to compare between the two Classes. For nonparametric data, Mann–Whitney *U* test was used to compare between males of both Classes. The frequencies, percentages (%) and results of Fisher’s exact test for comparison between smile arcs of Class I and Class III males on smiling are represented. The significance level was set at $P \leq 0.05$. Statistical analysis was performed with IBM SPSS Statistics for Windows, version 23.0. Armonk, New York: IBM Corp.

Results

Means, SD, 95% CI and results of student’s *t* test for comparison between esthetic soft tissue measurements for Class III and I males at rest and on smiling are presented in Tables 1 and 2.

As indicated in Table 1, at rest, there was no significant difference for all soft tissue measurements of Class I and Class III. On smiling, the maxillary incisor display for Class I was found to be significantly greater than that for Class III [Table 2]. The smile width and smile height for Class III was found to be significantly greater than that of Class I [Table 2].

Measurement (mm)	Class I (n = 15)		Class III (n = 15)		Mean Difference (mm)	95% CI for Difference		P-value	Effect size (d)
	Mean (mm)	SD	Mean (mm)	SD		Lower bound	Upper bound		
Upper lip length	20.27	2.29	19.92	3.82	0.35	-2.01	2.7	0.765	0.111
Upper lip thickness	5.9	0.96	6.11	1.7	-0.21	-1.25	0.82	0.676	0.152
Inter-commissural distance	47.58	2.78	5.68	5.68	-0.98	-4.32	2.36	0.553	0.219
Lower facial height	64.62	2.76	6.97	6.97	3.83	-0.14	7.79	0.058	0.723

Table 1: Comparison between soft tissue measurements of Class III and Class I males at rest.

Measurement (mm)	Class I (n = 15)		Class III (n = 15)		Mean Difference	95% CI for Difference		P-value	Effect size (d)
	Mean	SD	Mean	SD		Lower bound	Upper bound		
Maxillary incisor display	8.11	0.97	6.47	2.08	1.63	0.42	2.85	0.010**	1.011
Buccal corridors	7.01	0.91	8.28	2.59	-1.27	-2.72	0.19	0.085**	0.654
Gingival display	0.53	1.11	0.44	1.17	0.09	-0.76	0.95	0.749*	0.076 †
Smile width	60.66	6.22	67.17	7.44	-6.51	-11.64	-1.38	0.015**	0.949
Smile height	15.95	2.36	20.38	2.82	-4.43	-6.37	-2.48	<0.001***	1.704

*, Significant at $P \leq 0.05$, †: Mann-Whitney U test

** for ≤ 0.01

*** for ≤ 0.001

Table 2: Comparison of soft tissue measurements between males with Class III and I on smiling.

On the other hand, the gingival display and buccal corridors were found to be statistically insignificant between both groups [Table 2].

The smile arc was consonant in 93.3% of Class I and 60% of Class III while, nonconsonant smile arcs were seen in 6.7% of Class I and 40% of Class III males. However, it was found to be statistically insignificant at (P -value = 0.08, effect size 0.394). [Table 3].

	Class I (n = 15)		Class III (n = 15)		P-value	Effect size (v)
	N	%	N	%		
Consonant	14	93.3	9	60	0.08	0.394
Not consonant	1	6.7	5	40		

Table 3: Comparison between smile arcs of Class III and Class I males on smiling.

Inter-observer reliability (agreement)

All measurements were repeated for 10 frontal photographs by the main observer and another observer. There was good to very good inter-observer reliability (agreement) regarding all measurements of Class I cases with Cronbach's alpha values ranging from 0.608 to 0.812. Similarly with Class III cases; there was good to very good inter-observer reliability (agreement) regarding all measurements with Cronbach's alpha values ranging from 0.611 to 0.812 (Table 4).

<i>Class</i>	<i>Measurement</i>	<i>Cronbach's alpha</i>	<i>ICC</i>	<i>Measurement error</i>
Class I	Upper lip thickness	0.712	0.688	0.2
	Upper lip length	0.685	0.642	0.12
	Inter-commissural width	0.715	0.695	0.82
	Lower facial height	0.608	0.556	0.53
	Lower lip thickness	0.759	0.716	1.00
	Lower lip length	0.812	0.793	0.36
	Chin <i>height</i>	0.745	0.711	0.55
	Maxillary incisor display	0.732	0.704	0.67
	Buccal corridors	0.747	0.694	0.66
	Gingival display	0.791	0.758	0.37
	Smile width	0.688	0.649	0.74
	Smile height	0.700	0.685	0.95
Class III	Upper lip thickness	0.644	0.581	0.67
	Upper lip length	0.719	0.682	0.91
	Inter-commissural width	0.701	0.667	0.98
	Lower facial height	0.611	0.575	1.18
	Lower lip thickness	0.800	0.765	0.44
	Lower lip length	0.740	0.706	1.02
	Chin height	0.692	0.661	0.94
	Maxillary incisor display	0.736	0.712	0.84
	Buccal corridors	0.755	0.716	0.78
	Gingival display	0.816	0.800	0.67
	Smile width	0.652	0.633	1.18
	Smile height	0.726	0.711	0.99

Table 4: Results of Cronbach's alpha reliability coefficient and Intra-Class Correlation Coefficient (ICC) for inter-observer reliability.

Discussion

This study seeks to determine the smile characteristics of skeletal Class III compared to skeletal I male subjects. Two full face frontal photographs were taken for each participant at rest and with posed smile which is considered to be the most reproducible smile according to Ackerman *et al* [16]. According to Peck *et al*. [17] the essential characteristic of the smile that influences esthetics is the quantity of maxillary gingival display. In this study, the gingival display for skeletal Class III males was (0.44 mm) which was found to be significantly less than that seen for Class I males which was (0.53 mm) which was slightly more than the ideal amount of gingival display as reported by Chiche and Pinault [18] who pointed out that the esthetically perfect quantity of visible gingiva was about 1 mm but showed that 2-3 mm of gingiva might be esthetically satisfactory.

Although the upper lip length was no significantly longer for Class I compared to Class III males, the gingival display was not found to be greater in Class I males which could be due to significantly shorter lower facial height shown for Class I compared to Class III males in this study. According to Singer [19] & Peck *et al.* [17] those with gingival smiles were not only influenced by the upper lip length however, they were influenced by vertical maxillary excess and greater muscular capacity to raise the lips.

The intercommissure width at rest was found to be non-significant wider for both skeletal Class I and class III males, which was not in accordance with the results of Malhotra *et al.* [20] who explained that subjects with Class I showed maximum smile width. Abraham *et al.* [21] reported a positive correlation between the lower facial height and smile width which was in contrast to the findings of this study where Class III males showed wider smile widths associated with reduced lower facial height. The chin height was significantly longer for class I males compared to class III males which came in contrast to Farhard *et al.* [22] who reported that chin height was more significant in females than males.

In the present study, the buccal corridor shows insignificantly difference between both skeletal patterns which is in agreement with McNamara *et al.* [23] and Sachdeva *et al.* [24] who pointed out that buccal corridors in Class III subjects did not influence the smile.

In the present study, non-consonant and flat smile arcs represented a higher percentage in Class III compared to Class I males however, it was statistically insignificant which was in agreement with Sabri [25] and Camara [11] who concluded that insignificant difference in smile arcs were found among all malocclusions.

Conclusion

The maxillary incisor display for Class I was found to be significantly greater than that for Class III.

The smile width and smile height for Class III was found to be significantly greater than that of Class I.

Conflicts of Interest

None.

References

1. Simões D., et al. "Does the vertical position of maxillary central incisors in men influence smile esthetics perception?". *Am. J. Orthod Dentofacial Orthop* 156.4 (2019): 485-492.
2. Lima AP, et al. "Influence of facial pattern in smile attractiveness regarding gingival exposure assessed by dentists and laypersons". *Am. J. Orthod Dentofacial Orthop* 155.2 (2019): 224-233.
3. Parekh H., et al. "Smile - A Diagnostic Tool: photographic analysis in Adult Gujarati Population". *IOSR-JDMS* 12.4 (2013): 39-46.
4. Christou T, et al. "Clinical effectiveness of orthodontic treatment on smile esthetics: a systematic review". *Clin Cosmet Investig Dent* 11 (2019): 89-101.
5. Tosun H and Kaya B. "Effect of maxillary incisors, lower lip, and gingival display relationship on smile attractiveness". *Am. J. Orthod and Dentofacial Orthop* 157.3 (2020): 340-347.
6. Batwa W, et al. "Effect of occlusal plane on smile attractiveness". *Angle Orthod* 82.2 (2012): 218-223.
7. Godinho J, et al. "Contribution of facial components to the attractiveness of the smiling face in male and female patients: A cross-sectional correlation study". *Am. J. Orthod and Dentofacial Orthop* 157.1 (2020): 98-104.
8. Pithon MM, et al. "Do dental esthetics have any influence on finding a job?". *Am J Orthod Dentofacial Orthop* 146.4 (2014): 423-429.
9. De Clerck HJ and Proffit WR. "Growth modification of the face: a current perspective with emphasis on Class III treatment". *Am J Orthod Dentofacial Orthop* 148.1 (2015): 37-46.

10. Ngan P, et al. "Treatment of Class III problems begins with differential diagnosis of anterior crossbites". *Pediatr Dent* 19.6 (1997): 386-395.
11. Câmara CA. "Aesthetics in Orthodontics: Six horizontal smile lines". *Dental Press J. Orthod* 15 (2010): 118-131.
12. Ackerman MB and Ackerman JL. "Smile analysis and design in the digital era". *J Clin Orthod* 36.4 (2002): 221-236.
13. Kakadiya J, et al. "An evaluation of smile in different malocclusion of local population–A pilot study". *J Dental Med Sci* 14 (2015): 25-32.
14. Leonardi R, et al. "Soft tissue changes following the extraction of premolars in nongrowing patients with bimaxillary protrusion". A systematic review. *Angle Orthod* 80.1 (2010): 211-216.
15. Nouh AS, et al. "Evaluation of smile characteristics of skeletal Class III compared to skeletal Class I female adults". *J Orthodont Sci* (2021).
16. Ackerman JL, et al. "A morphometric analysis of the posed smile". *Clin Orthod Res* 1.1 (1998): 2-11.
17. Peck S, et al. "The gingival smile line". *Angle Orthod* 62.2 (1992): 91-100.
18. Chiche G and Pinault A. "Diagnosis and treatment planning of esthetic problems". *Esthetics of Anterior Prosthodontics*. Quintessence Publishing Co Inc., United States (2004): 13-25.
19. Singer R. "A study of the morphometric, treatment and esthetic aspects of gingival display". *Am J Orthod* 65 (1974): 435-436.
20. Malhotra S, et al. "Characterization of a posed smile and evaluation of facial attractiveness by panel perception and its correlation with hard and soft tissue". *Orthodontics (Chic.)* 13.1 (2012): 34-45.
21. Abraham A, et al. "Establishment of a new relationship between posed smile width and lower facial height: A cross sectional study". *Eur J Dent* 9.3 (2015): 394-399.
22. Farhard BN, et al. "Influence of chin height on perceived attractiveness in orthognathic patient, layperson, and clinician". *Angle orthodontist* 82.1 (2012): 88-95.
23. McNamara L, et al. "Hard and soft tissue contributions to the esthetics of the posed smile in growing patients seeking orthodontic treatment". *Am J Orthod Dentofacial Orthop* 133.4 (2008): 491-499.
24. Sachdeva K, et al. "Esthetic and smile characteristics at rest and during smiling". *J Ind Orthod Soc* 46.1 (2012): 17-25.
25. Sabri R. "The eight components of a balanced smile". *J Clin Orthod* 39.3 (2005): 155-167.

Volume 1 Issue 3 October 2021

© All rights are reserved by Abdallah S Nouh., et al.