

Garre's Osteoperiostitis: From Diagnosis To Treatment

Ameni Chadlia Belghuith¹, Amira Kikly², Foued Brigui¹, Wided Glii¹, Neila Zokkar³ and Nabiha Douki^{3*}

¹DDS, Department of Dentistry, university hospital, Sahloul, Tunisia; Faculty of Dental Medicine, University of Monastir, Avicenna Street, 5000 Tunisia; Research Laboratory LR12ES11, University of Monastir

²DDS, Associate professor, Department of Dentistry, university hospital, Sahloul, Tunisia; Faculty of Dental Medicine, University of Monastir, Avicenna Street, 5000 Tunisia; Research Laboratory LR12ES11, University of Monastir

³DDS, Professor, Department of Dentistry, university hospital, Sahloul, Tunisia; Faculty of Dental Medicine, University of Monastir, Avicenna Street, 5000 Tunisia; Research Laboratory LR12ES11, University of Monastir

***Corresponding Author:** Nabiha Douki, DDS, Professor, Department of Dentistry, university hospital, Sahloul, Tunisia; Faculty of Dental Medicine, University of Monastir, Avicenna Street, 5000 Tunisia; Research Laboratory LR12ES11, University of Monastir.

Received: September 10, 2023; **Published:** October 28, 2023

Abstract

Garre's osteoperiostitis is a chronic osteomyelitis with proliferative periostitis, usually associated with a mild odontogenic infection. A patient was referred to us because of a hard and slightly painful mandibular swelling that had persisted for two months. After clinical and radiological exploration (panoramic, occlusal radiography, CBCT), the diagnosis of Garre's Osteoperiostitis was evoked. Management consisted of endodontic treatment. After a 6-month follow-up, the periosteal reaction regressed and the mandibular swelling disappeared. After the elimination of the infectious focus, the bone gradually remodels and the original facial symmetry is restored the bone progressively r. The treatment will be followed by clinical and radiographic control after 8 and 12 months until complete bone healing is observed. Periostitis ossificans in the young is usually curable with early diagnosis and proper treatment. When the clinical situation permits, endodontic therapy should be the choice of treatment. The objective of this work is to illustrate the clinical and radiographic aspect, the management as well as the postoperative follow-up of such a pathology.

Keywords: osteoperiostitis; necrotic tooth; endodontic treatment

Introduction

Garre's osteoperiostitis is a particular type of chronic sclerotic osteomyelitis, affecting mainly children and adolescents, the mandible more than the maxilla, with a prevalence in the posterior sector. It is characterized by a rigid bony swelling at the periphery of the jaw following a chronic low-grade odontogenic infection [1], and is also known as Garre's osteomyelitis and chronic osteomyelitis with proliferative periostitis. This pathological entity was first described by Carl Garré in 1893 [2].

Periostitis ossificans is generally curable with early diagnosis and appropriate treatment. When the clinical situation allows, endodontic therapy should be the main choice of treatment. Once the cause has been eliminated, the bone gradually remodels and the original facial symmetry is restored. However, if correct diagnosis is delayed for more than 6 months, the condition may progress to a persistent, deforming stage [3].

The aim of this work is to present the clinical and radiographic signs of a diagnosed case of Garre's osteoperiostitis of infectious dental origin and to discuss the therapeutic modalities.

Case report

An 11-year-old girl in good general condition was referred for a mandibular swelling that had persisted for two months. The patient had received antibiotic therapy for 7 days (Augmentin®). Extraoral inspection revealed facial asymmetry due to a firm, non-tender mass on the lateral aspect of the left mandibular region. The overlying skin was unremarkable and no fluctuation or discharge was noted (Fig.1). Palpation revealed no adenopathy, and general condition was unaltered.

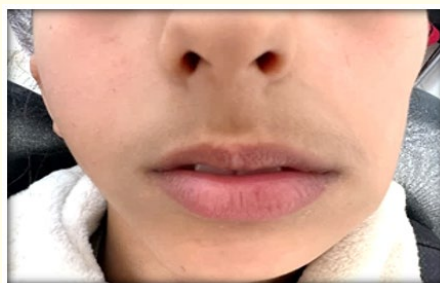

Figure 1: Exo buccal clinical view reveals a left mandibular swelling.

Intraoral examination revealed that the left mandibular first molar (36) was necrotic and showed a Sista 1.4 carious lesion. The tooth was sensitive to axial and transverse percussion, with no mobility.

Panoramic radiography showed a periapical lesion (Fig.2). Occlusal radiography revealed thickening of the vestibular periosteum (Fig.3). CBCT was ordered as a second-line procedure and showed a 2-layer, 4mm-thick periosteal reaction extending from 34 to 37 with an "onion-skin" appearance (Fig.4, Fig.5).

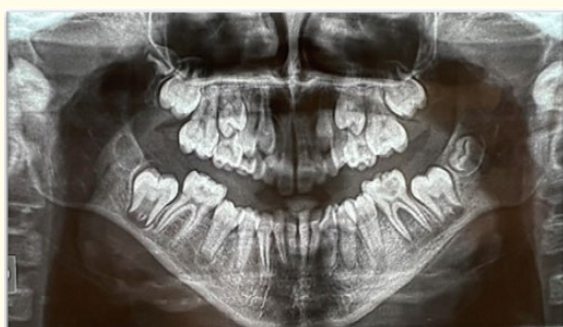

Figure 2: Panoramic radiography.

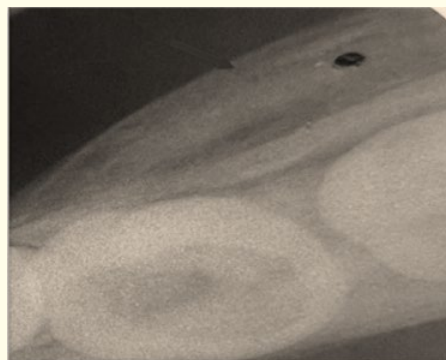
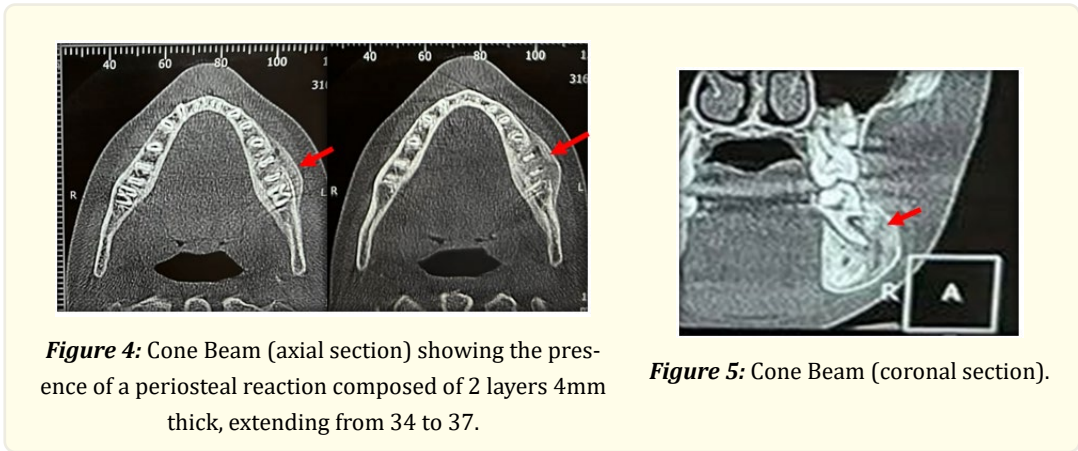
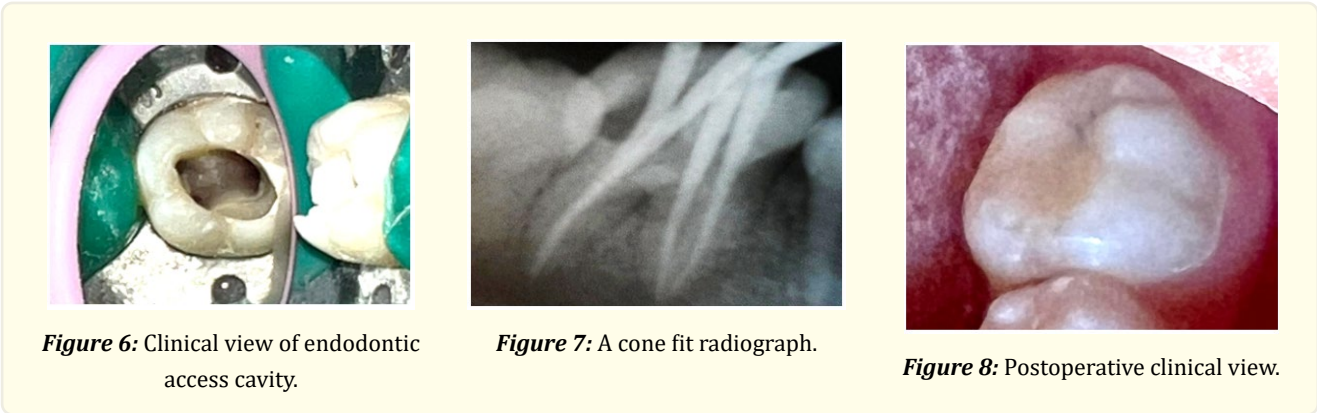


Figure 3: Occlusal radiography showing thickening of the vestibular periosteum.



The diagnosis of Garre's periostitis associated with odontogenic infection of the left mandibular first molar (36) was confirmed by clinical and radiographic signs, as well as by the causal relationship with endodontic infection. Full shaping (with a mechanized 6% taper system) with abundant sodium hypochlorite irrigation was performed on the first session (Fig.6) and calcium hydroxide-based endodontic medication was applied for two weeks without additional antibiotic therapy.

At the second appointment, a definitive root canal filling using the lateral cold condensation technique (Fig.7) was performed, followed by a definitive coronal composite resin filling (Fig.8). Clinical and radiological follow-up was instituted.



After 6 months, the tooth was asymptomatic and functional. Clinical healing with disappearance of mandibular swelling (Fig.9) and periapical radiolucency on retroalveolar radiography (Fig.10) was observed. Occlusal radiography showed the disappearance of external bone formation, indicating complete healing of the periosteal reaction (Fig.11).

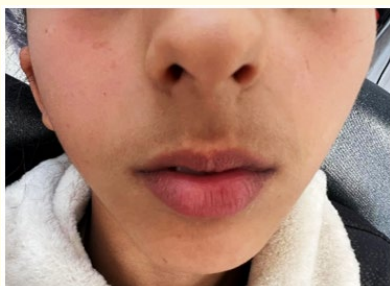


Figure 9: Clinical recovery after 6 months with disappearance of exobuccal swelling.

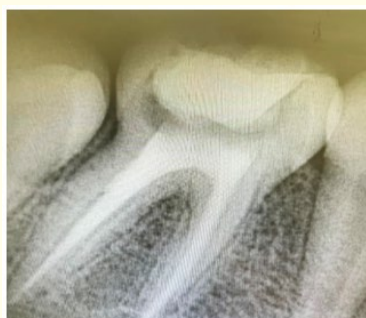

Figure 10: Retroalveolar radiograph after 6 months: total regression of apical radiotclarity.

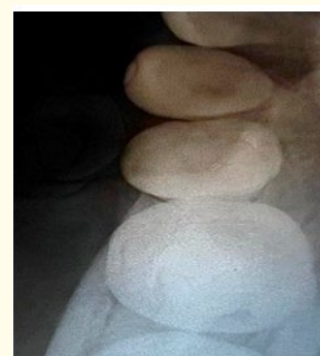

Figure 11: Control occlusal radiography showing disappearance of periostitis after 6 months.

Discussion

Etiopathogeny

In our case, the causative agent was pulpal necrosis of the left lower first molar associated with chronic periapical infection. This infection spread to the cancellous bone and then to the cortical bone on the lateral aspect of the mandible. The inflammatory process spread and exerted pressure on the periosteum irritated by noxious stimuli, leading to stimulation of osteoblasts to form the initial bone. Under the influence of episodic stimuli, bone formation continued in the form of successive layers of bone. Gradually, the cortex thickened to give a lamellar structure known as “onion skin” [4, 5].

It has been found that the size of the swelling can vary from 1 to 2 cm, reaching the entire length of the jaw on the affected side, and the thickness of the newly formed bone can reach 2 to 3 cm [5]. Subjective signs can be variable. The patient's history usually reveals episodic pain with periods of inactivity and progressive swelling. The degree and duration of symptoms depend on several factors, such as the virulence of the causative germs, the presence of underlying diseases and the immune status of the host.

This gradual evolution reveals the benign nature of this pathology, in contrast to malignant pathology, which is often characterized by a rapid evolution of symptoms [6]. In our case, the patient was referred for persistent mandibular swelling, evolving for two months and presenting a history of intermittent dental pain.

Differential diagnosis

Periostitis ossificans must be distinguished from benign and malignant bone-forming pathologies. Most of them usually develop in the same age group. Fibrous dysplasia can be observed at an early age, and bone proliferation is similar to periostitis in shape and volume. However, fibrous dysplasia is distinguished by its “ground-glass” radiographic appearance and thinning of the cortex [7, 8]. Ewing's sarcoma and osteosarcoma are distinguished by clinical complications such as tooth mobility, facial neuralgia and labial par-esthesia, as well as the “sunburst” radiological appearance [9, 10].

Caffey's disease is a genetic bone disorder that may have the same “onion-skin” appearance as periostitis ossificans. It is distinguished by its bilateral involvement, its presence in several foci and its early onset (before the age of two). It is most common in the ramus and mandibular angle region [10] Primary tuberculous osteomyelitis is a rare form of osteomyelitis caused by tuberculosis. In children, it is most common in the maxilla. Clinically, it is characterized by pain, swelling and disturbance of the intra- or extra-oral

sinus tract. Radiographically, it presents as a blurred radiolucency with cortical erosion. The bone is progressively replaced by granular tissue. Pathologically, the diagnosis can be confirmed by the presence of tubercular granulomas [11]. Primary chronic osteomyelitis (PCO) is a chronic, non-bacterial inflammatory disease. It is not very common, and its etiology is still unknown.

It may be associated with other pathologies, such as autoimmune diseases and syndromes (e.g. cherubism, SAPHO syndrome...) [12].

In our case, a dental infection was at the origin of the lesion. The diagnosis was based on the radiographic appearance, in particular the "onion-peel" appearance, and clinical signs such as slow evolution, young age, absence of tooth mobility and hypoesthesia, as well as favorable evolution after treatment. Generally, clinical and radiological signs confirm the diagnosis, but histological examination is sometimes necessary to confirm the pathology in progress.

This examination reveals fibro-osseous tissue with peripheral osteoblastic activity due to new reactive bone deposition. The presence of central osteoblasts and osteoclasts, lymphocytes and plasma cells in the medullary space is also confirmed by this examination [13].

Treatment

In the past, and for many years, treatment of Garre's osteoperiostitis was radical, based on extraction of the causal tooth with long-term antibiotic therapy. Today, different opinions have emerged concerning the most appropriate treatment for this pathology, which may be conservative or radical, with or without antibiotic therapy. Where the clinical situation allows, endodontic treatment should be the main therapeutic choice. Indeed, it has been proven in some reported cases that endodontic treatment alone is sufficient and capable of resolving this pathology [14, 15].

In addition, hyperbaric oxygen therapy and endodontic treatment proved effective. In our case, endodontic treatment was chosen because of the patient's young age, the possibility of preserving the tooth and the positive attitude of the patient and her parents. Indeed, an optimal prognosis depends on the ability to create conditions conducive to adequate healing. To improve the success rate of endodontic treatment, we need to focus more on the chemical and mechanical preparation of the root canal system. In fact, root canal disinfection is the key to eradicating root canal infection, leading to periapical healing.

Strategies recommended to improve disinfection after root canal preparation include the use of endodontic medication inter-sessionally or optimized endodontic treatment in a single visit. However, this subject is still debated, and some studies have reached controversial conclusions. Indeed, a number of studies using microbial culture have confirmed the value of using calcium hydroxide (CaOH₂)-based endodontic medication to complement root canal disinfection. While many other studies have shown that the two-visit protocol involving intersessional medication can cause bacterial multiplication in the root canal system compared to the one-visit protocol. They suggested that residual microorganisms may be walled up by the root canal filling in the absence of nutrients. For our clinical case, treatment was performed in two sessions and CaOH₂-based medication was applied for two weeks to optimize root canal disinfection [17, 18].

As regards antibiotic therapy, according to the literature, there is no consensus on its use or on the duration of treatment, which varies from six weeks to twelve months [19, 20]. In our case, the patient received antibiotic therapy for seven days (Augmentin®), and the prescription was not renewed. Regular follow-up is crucial until complete healing is achieved. Biopsy is indicated if the lesion continues to increase in size after apparently successful treatment [14]. For lesions of limited size, the prognosis is favorable and regression can be observed within a few months. Surgical remodelling can be performed in the absence of regression.

In our clinical case, complete periapical healing was observed at 6 months, and bone healing was noted without any further complications. Surgery was not necessary, as the response to conventional endodontic treatment was favorable.

Conclusion

Garre's osteoperiostitis is a coexisting pathology with certain conditions, including chronic infection in young patients, energetic osteoblastic activity in the periosteum and, finally, a balance between the virulence of the causative agent and host resistance [21]. Particular attention must be paid to clinical and radiographic investigations in cases of mandibular swelling, so as not to miss any malignant bone disease.

References

1. Neville BW, et al. "Pulpal and periapical diseases. osteomyelitis with proliferative periostitis (Periostitis ossificans) Oral and Maxillofacial Pathology". 4th ed St Louis Saunders (2016): 134-6
2. Garré C. "About special forms and subsequent states d. acute infection". Osteomyelitis Beitr z klinChir 10 (1893): 257.
3. Kannan SK, Sandhya G and Selvarani R. "Periostitis ossificans (Garre's osteomyelitis) radiographic study of two cases". Int J Paediatr Dent 16.1 (2006): 59-64.
4. Eyrich GK, et al. "Primary chronic osteomyelitis in childhood and adolescence: A retrospective analysis of 11 cases and review of the literature". J Oral Maxillofac Surg 61 (2003): 561-73.
5. Erişen M, Bayar OF and Ak G. "Garre osteomyelitis: a case report". J Dent Fac Atatürk Univ 9 (2014): 49-53.
6. Eyrich GK, et al. "Primary chronic osteomyelitis in childhood and adolescence: A retrospective analysis of 11 cases and review of the literature". J Oral Maxillofac Surg 61 (2003): 561-73.
7. Petrikowski CG, et al. "Radiographic differentiation of osteogenic sarcoma, osteomyelitis, and fibrous dysplasia of the jaws". Oral Surg Oral Med Oral Pathol Oral RadiolEndod 80 (1995): 744-50.
8. Suma R, et al. "Garre's sclerosing osteomyelitis". Journal of the Indian Society of Pedodontics and Preventive Dentistry 25 (2007): 30-33.
9. White SC and Pharoah MJ. Oral Radiology: Principles and Interpretation. 6th edition (2009).
10. Karjodkar FR. Textbook of Dental and Maxillofacial Radiology, Panama, Jaypee Brothers Medical Pub, 2nd edition (2009).
11. Kalaiarasi R, et al. "Pediatric primary tuberculous osteomyelitis of the mandible mimicking parotitis". Cureus10.1 (2018): e2071.
12. Stern SM and Ferguson PJ. "Autoinflammatory bone diseases". Rheumatic Disease Clinics 39.4 (2013): 735-749.
13. Martin-Granizo R, et al. "Mandibular sclerosing osteomyelitis of Garre". Otolaryngology-Head and Neck Surgery 121.6 (2016): 828- 829.
14. Gonçalves M., et al. "Garre's osteomyelitis associated with a fistula: a case report". The Journal of Clinical Pediatric Dentistry 26.3 (2002): 311-313.
15. Nakano H, et al. "Garre osteomyelitis of the mandible caused by an infected wisdom tooth". Int J Oral Sci 52.4 (2014): 496-500.
16. Akgül HM, et al. "Garre's osteomyelitis of the mandible caused by infected tooth". Case Reports in Dentistry (2018): 1-4.
17. Vera J, et al. "One- versus two- visit endodontic treatment of teeth with apical periodontitis: a histobacteriologic study". Journal of Endodontia 38.8 (2012): 1040-1052.
18. Brazão-Silva MT and Pinheiro TN. "The so-called garre's osteomyelitis of jaws and the pivotal utility of computed tomography scan". Contemp Clin Dent 8.4 (2017): 645- 646.
19. Nakano H, et al. "Garre osteomyelitis of the mandible caused by an infected wisdom tooth". Int J Oral Sci 52.4 (2014): 496-500.
20. Bah A, et al. "Management of chronic dental osteoperiostitis in children: A case report". Afr J Dent Implantol 7 (2016): 52-60.
21. Erişen M, Bayar OF and Ak G. "Garre osteomyelitis: a case report". J Dent Fac Atatürk Univ 9 (2014): 49-3.

Volume 3 Issue 2 November 2023

© All rights are reserved by Nabih Douki, et al.