

## Scope And Suction: Reexpansion Pulmonary Edema (Repe), A Complication Post-Bronchoscopy to Be Aware Of

**Nik Ahmad Hatim Nik Mohammad Dziauddin\* and Abu Yazid Md Noh**

*Department of Emergency Medicine, Hospital Universiti Sains Malaysia, Kota Bharu, Kelantan, Malaysia*

**\*Corresponding Author:** Nik Ahmad Hatim Nik Mohammad Dziauddin, Department of Emergency Medicine, Hospital Universiti Sains Malaysia, Kota Bharu, Kelantan, Malaysia.

**Received:** December 14, 2024; **Published:** February 08, 2025

### Abstract

Reexpansion pulmonary edema (REPE) is acute lung injury (ALI) with incidence of less than 1% following pneumothorax or pleural effusion evacuation, which may also occur due to excessive suction of tracheobronchial tree during bronchoscopy. 63 year old lady with hypertension and stroke presented to emergency in septic shock with temperature of 38.7°C. She had respiratory distress with lung finding of left lower zone coarse crepitation and fail to saturate in spite high-flow mask oxygen. She was intubated for impending respiratory collapse and ultrasound showed right femoral vein thrombosis with CT pulmonary angiogram confirmed of pulmonary embolism. Antibiotic and anticoagulant were started for initial treatment. Later, patient required bronchoscopy for collapse and consolidation of left lower lobe as evidence by chest X-ray. Thick mucus over left upper and lower lobes were sucked out. Immediately post procedure, patient desaturated to 90% and required greater positive end-expiratory pressure (PEEP) to maintain saturation. Repeated chest X-ray suggest left upper lobe collapse and lower lobe REPE. With adequate PEEP, REPE and lung collapse were resolved. This case describes rarely discussed complication of bronchoscopy that should be recognized as bronchoscopy is a valuable tool for diagnosing and treating airway issues in emergency settings nowadays.

**Keywords:** Reexpansion pulmonary edema; acute lung injury; bronchoscopy

### Introduction

Reexpansion pulmonary edema (REPE) is an atypical acute lung injury (ALI) with incidence of less than 1% following pneumothorax or pleural effusion evacuation [1], which may also occur due to excessive suction of tracheobronchial tree during bronchoscopy [2].

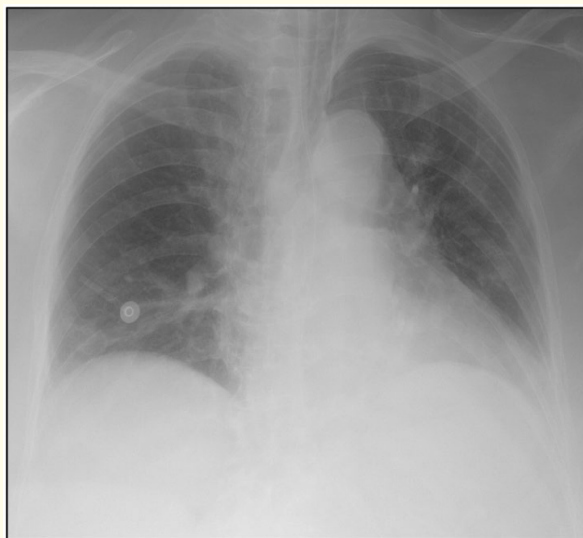Stawicki SP et al. suggest that the primary risk factor related to the occurrence of REPE are reinflation of collapsed lung parenchyma after pulmonary collapse lasting for more than 72 hours. Others may include the amount of fluid, air, or mass occupying the intrathoracic space; clinical variables related to pulmonary reexpansion techniques or procedures; presence of bronchial obstruction; use of excessive suction during bronchoscopy or tracheal suctioning; changes in pulmonary artery pressure; removal of large extrathoracic lesions that compress the thoracic cavity; and finally, those at younger age may also be at risk of developing REPE [2].

A strong correlation between clinical history, clinical presentation, and radiographic evidence is essential for the diagnosis of REPE. Radiographic imaging will typically reveal interstitial opacities, pulmonary consolidations, air bronchograms, pulmonary clefts, and the presence of Kerley B lines, which collectively suggest the presence of pulmonary edema. Consideration should be given to other possibilities, including cardiogenic pulmonary oedema, pneumonitis, and pulmonary infection [3].

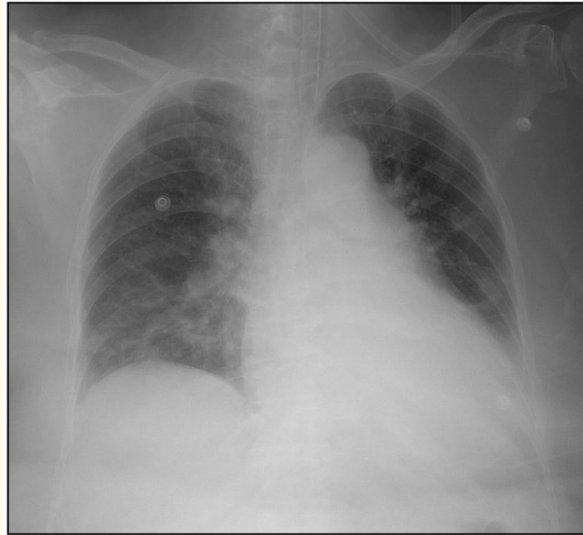
## Case

A 63-year-old Malay lady with hypertension and ischemic stroke was bedridden for over two months after a history of fall in the toilet. She presented to emergency department with three days history of fever, lethargy, and poor appetite. Her blood pressure was 123/74 mmHg with a heart rate of 140 beats/min, and clinically was in compensated shock with a documented temperature of 38.7°C. She was in severe respiratory distress and unable to saturate in spite of non-rebreather high-flow mask oxygen. Physical examination of her lung shows left lower zone coarse crepitations. Her Glasgow Coma Scale was 13/15 (E4V4M5), and capillary glucose was at 6.1 mmol/L. There was left lower limb swelling, erythematous, and ruptured bullae, which resembled bullous cellulitis. Point of care ultrasound (PoCUS) showed a confluent B-line over L4, a hyperdynamically contracting heart, a collapsible inferior vena cava of more than 50%, and the presence of a thrombus in the right common femoral vein. She was subsequently intubated for impending respiratory collapse, and later requiring dual inotropes due to a non-fluid-responsive hypotensive episode. Her chest X-ray was suggestive of left lower lobe pneumonia and suspicious of pulmonary embolism, which was then confirmed by a CT pulmonary angiogram.

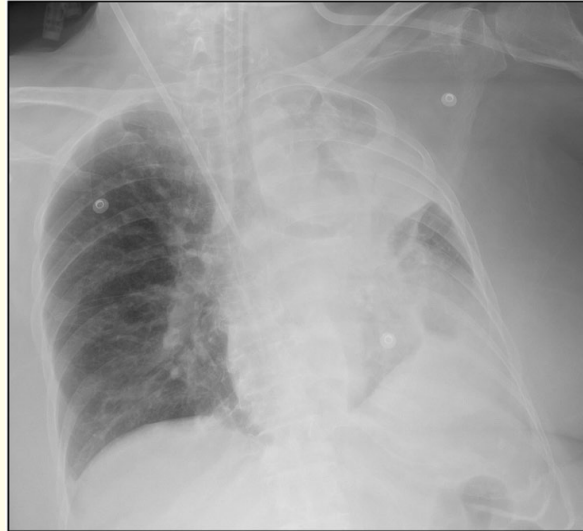She was treated for septic shock caused by community-acquired pneumonia and bullous cellulitis in the left lower leg, with concomitant acute submassive pulmonary embolism and right lower limb deep vein thrombosis. Antibiotics and anticoagulants were started as part of the initial treatment. Later, the patient required bronchoscopy due to prominent features of collapse and consolidation over the left lower lobe in keeping with the absence of left-sided diaphragmatic outlines based on repeated chest X-rays. Bronchoscopy was done and noted thick mucous secretions over the left upper and lower lobes, which were sucked out. Post-procedure, the patient desaturate down to 90% and required a greater PEEP to maintain her saturation. Repeated chest X-rays suggest unilateral left upper lobe lung collapse and lower lobe REPE. The figure below illustrates the chest X-rays associated with this case, beginning with the initial encounter, pre-bronchoscope, immediate post-bronchoscope, and later post lung recruitment.



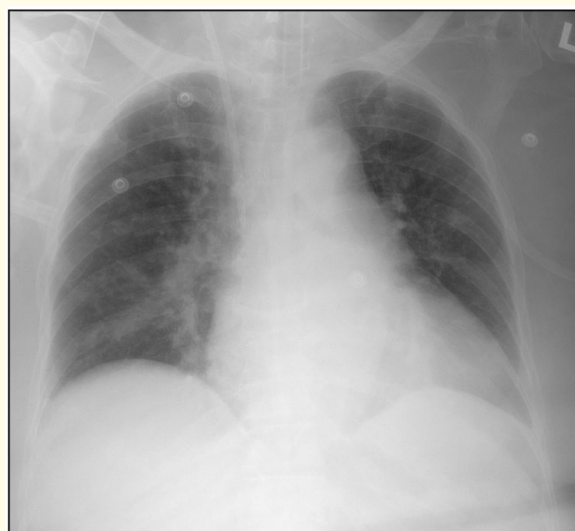**Figure 1:** Chest X-ray upon initial encounter at emergency.



**Figure 2:** Chest X-ray pre-bronchoscope.



**Figure 3:** Chest X-ray post-bronchoscope.



**Figure 4:** Chest X-ray post-recruitment.

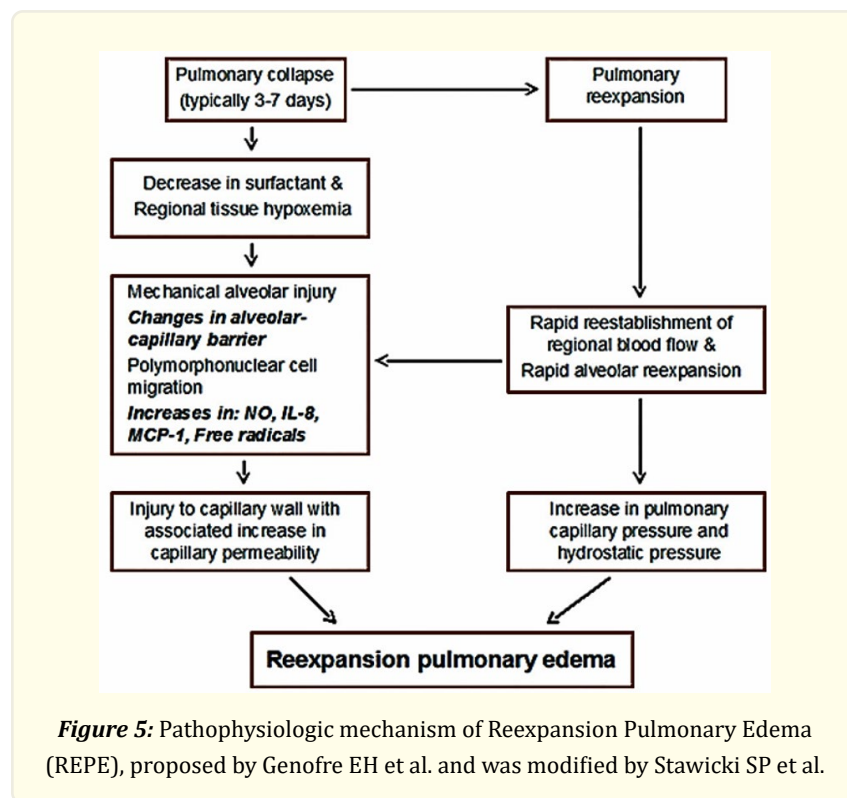
With adequate PEEP upon ventilatory support and clinical manoeuvres by positioning patient to right lateral decubitus with the affected left side facing up, REPE as well as the collapse and consolidation of the left lower lobe were resolved.

## Discussion

Although emergency bronchoscopy is not yet a regular procedure in the emergency department [4], emergency physicians, particularly those specialised in critical care, have adopted bronchoscopy as a valuable tool for diagnosing and treating airway management issues [5]. In reference to this case, it is crucial for physicians doing the procedure to be mindful that excessive suctioning of the tracheobronchial tree increases the patient's risk of developing REPE.

The presentation of REPE can range from mild or absent symptoms to severe, life-threatening hypoxia, hemodynamic instability, and even death. Patients may present with dyspnea, chest pain, and a cough that may or may not produce pink, frothy sputum. Additional potential manifestations encompass cyanosis, fever, nausea, vomiting, tachycardia, and hypotension, as well as the presence of rales and stertorous breath sounds on auscultation [2].

As for REPE, it has been understood that once there is pulmonary collapse, the production of surfactant is reduced, and this may also favour regional tissue hypoxemia. The correction of the pulmonary collapse may result in pulmonary reexpansion, which will rapidly cause a reestablishment of regional blood flow as well as abrupt alveolar reexpansion. As a result, there will be a mechanical alveolar injury, which will compromise the alveolar capillary barrier's integrity and make it worse by migrating polymorphonuclear cells, which will release the neutrophil granular contents and lead to elevations of interleukin-8, monocyte chemoattractant protein-1, nitric oxide, and free radicals. This will lead to injuries to capillary walls and an increase in capillary permeability. Therefore, when coupled with the increase in hydrostatic and pulmonary capillary pressure, this could potentially result in devastating acute lung injury. Those pathophysiologic mechanism was proposed by Genofre EH et al. and was subsequently modified by Stawicki SP et al., as illustrated in the diagram provided below [2, 6].



Supplemental oxygen administration, proper ventilation support (invasive vs. non-invasive), vasopressor and/or inotropic drug use, careful diuresis, and haemodynamic monitoring are crucial components to consider when handling such situations. Additionally, tracheal intubation with the appropriate use of positive end-expiratory pressure is advised in cases with extreme severity [6-11]. The related considerable mortality (as high as 21%) makes prevention of REPE by acknowledging the risk factors the most effective clinical approach, regardless of the treatment modalities available [6]. In conclusion, it is important to emphasize that the patient likely experienced REPE, which can be attributed to the rapid reinflation of collapsed lung parenchyma following excessive suctioning of the tracheobronchial tree during bronchoscopy.

### Competing interests

The authors declare that they have no competing interests.

### Reference

1. Stawicki SP, Sarani B and Braslow BM. Reexpansion pulmonary edema 2.2 (2008): 29-31.
2. Stawicki S, Sarani B and Braslow B. "Reexpansion pulmonary edema". International Journal of Academic Medicine 3.3 (2017): 59.
3. Gluecker T, et al. "Clinical and Radiologic Features of Pulmonary Edema". Radiographics 19.6 (1999): 1507-1531.
4. Singh G. "Significance of Emergency Bronchoscopy; Significance in Essential Emergency Critical Care Setting". Malaysian Journal of Medical Research 07.02 (2023): 40-44.
5. Adi O, et al. "Emergency physician-performed emergency bronchoscopy in cardiac arrest patient due to acute foreign body airway obstruction". The American Journal of Emergency Medicine 53 (2022): 23-28.
6. Genofre EH, et al. "Reexpansion pulmonary edema". Jornal De Pneumologia 29.2 (2003): 101-106.
7. Mahajan VK, Simon M and Huber GL. "Reexpansion pulmonary edema". Chest 75 (1979): 192 4.

8. Mahfood S, et al. "Reexpansion pulmonary edema". *Ann Thorac Surg* 45 (1988): 340-5.
9. Yanagidate F, et al. "Reexpansion pulmonary edema after thoracoscopic mediastinal tumor resection". *Anesth Analg* 92 (2001): 1416-7.
10. Otomo A., et al. "Reexpansion pulmonary edema after removal of a giant thoracic tumor associated with long-time lung collapse and mediastinal shift". *Masui* 53 (2004): 291-3.
11. Tariq SM and Sadaf T. "Images in clinical medicine. Reexpansion pulmonary edema after treatment of pneumothorax". *N Engl J Med* 354.19 (2006): 2046.

**Volume 8 Issue 2 February 2025**

**© All rights are reserved by Nik Ahmad Hatim Nik Mohammad Dziauddin., et al.**