

Growth Factor as Regenerative Materials in Oral Surgery Management of Periapical Lesions

Patroklos Konstantinos Alevizos^{1,4}, Ioannis Trigkas^{1,4}, Magda Koskieri^{1,4}, Stella^{1,4}, Stavros Tsantis³, Edit Xhanjanka⁴, Lucas Chatzikonstantis^{1,4}, Pantelis Kavrulakis^{1,4}, Johnny Mahfod^{1,4}, Ioannis P Georgakopoulos^{1,2,4} and Alaa Abu Shareia^{1,2,4*}

¹WAGRO (World Academy of Growth Factors & Stem Cells in Dentistry), Greece

²WAGRO University, USA

³Department of Medical Physics, School of Medicine, University of Patras, Rion, Greece

⁴PgO-UCAM, Catholic University of Murcia, Spain

***Corresponding Author:** Professor. Dr. Alaa Abu Shareia. MSc. DSc., WAGRO (World Academy of Growth Factors & Stem Cells in Dentistry), Greece; WAGRO University, USA; PgO-UCAM, Catholic University of Murcia, Spain.

Received: March 01, 2024; **Published:** March 19, 2024

DOI: 10.55162/MCMS.06.203

Abstract

This research aims to clarify the PRF / CGF membranes and sticky bone preparation together with other platelet concentrates. A few clinical cases will show how sticky bone is together with PRF membranes applicative in different oral surgery indications [1]. Growth Factor are polypeptide hormones or biological factors. They mediate many cellular processes for the various stages of growth. Endodontic therapy, commonly known as root canal treatment, is indeed highly successful in most cases, with success rates typically ranging from 85% to 97%. However, in a minority of cases, symptoms may persist or reoccur despite initial treatment. In such situations, periapical surgery, also referred to as apical surgery or apicoectomy, may be recommended as the next step. Periapical surgery involves accessing the tip of the tooth's root (apex) and removing any infected tissue or lesions in the surrounding area. This procedure is often indicated when conventional root canal treatment has failed, or when there are persistent issues such as chronic periapical lesions or apical periodontitis. During periapical surgery, the endodontist or oral surgeon will make a small incision in the gum tissue near the affected tooth to access the root tip. The infected tissue is then removed, and the tip of the root may be reshaped or sealed to prevent further infection. Finally, the gum tissue is sutured back into place.

Keywords: Autologous platelets concentrate; concentrated growth factor; endodontic surgery; sticky bone

Abbreviations

There are no articles published in the literature with respect to the potent application of CGF and bone graft (sticky bone) in large periapical lesions to aid in the reparative process. In this cases report, the 1-year follow-up radiographs showed complete healing of the hard and soft-tissue lesions that conform to achieving repair and regeneration at a rapid rate in extensive periapical lesions [7].

Introduction

A thorough search of the literature disclosed the absence of any publication with reference to the use of sticky bone in endodontic surgical procedures, thus highlighting the uniqueness of this case report in that regard.

In 1976, melcher proposed the initial hypothesis on the potential of periodontal regeneration. Currently utilized regenerative techniques incorporate guided tissue regeneration (GTR), alone or with bioabsorbable or nonresorbable membranes, allograft and bone autographs, and agents such as citric acid or tetracycline used to condition roots and enhance the attachment of periodontal tissues. Periapical surgery is generally considered a last resort when other treatment options have been exhausted, as it is more invasive than conventional root canal therapy. However, it can be highly effective in resolving persistent or recurrent symptoms and saving the tooth from extraction. Over the past few decades, although the list of indications for endodontic surgery has diminished, there exist definite cases in which the tooth cannot be retained without surgery. This case report, however, sheds light on the incorporation of a novel autologous platelet concentrate-concentrated growth factor (CGF) coupled with an osseograft in surgical endodontic procedure to ensure a swift and successful recovery of the periapical region subjected to extensive lesions.

The use of an osseograft combined with CGF has numerous advantages as well due to the formation of sticky bone.

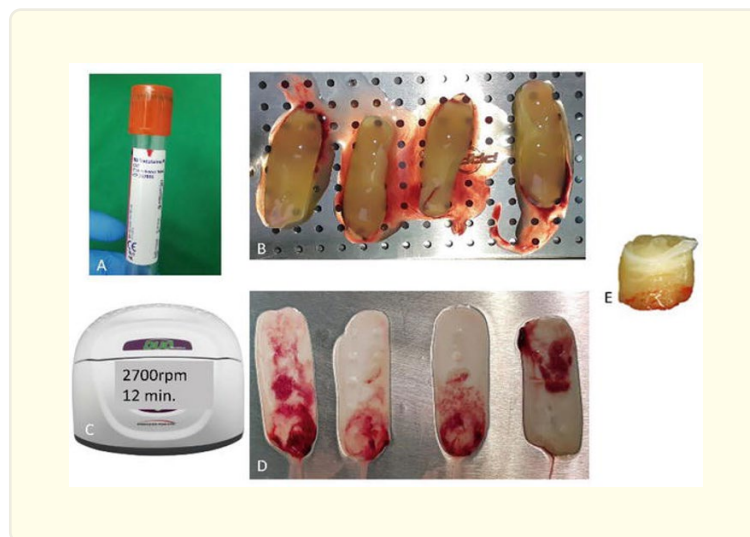There are no articles published in the literature with respect to the potent application of CGF and bone graft (sticky bone) in large periapical lesions to aid in the reparative process. In this case report, the follow-up radiographs showed complete healing of the hard and soft-tissue lesions that conform to achieving repair and regeneration at a rapid rate in extensive periapical lesions.

The concept of surgical endodontics dates to 1500 years from the pioneering work initiated by Aetius, based on incision and drainage [3] and has been a major breakthrough ever since. Surgical debridement and resective techniques have been the traditional approaches practiced enhancing periapical healing thereby seizing disease progression.

Wherein they assessed the radiographic size of lesions and finally concluded that if the lesion does not involve the apex with an intact epithelial lining, it may not heal nonsurgical [2].

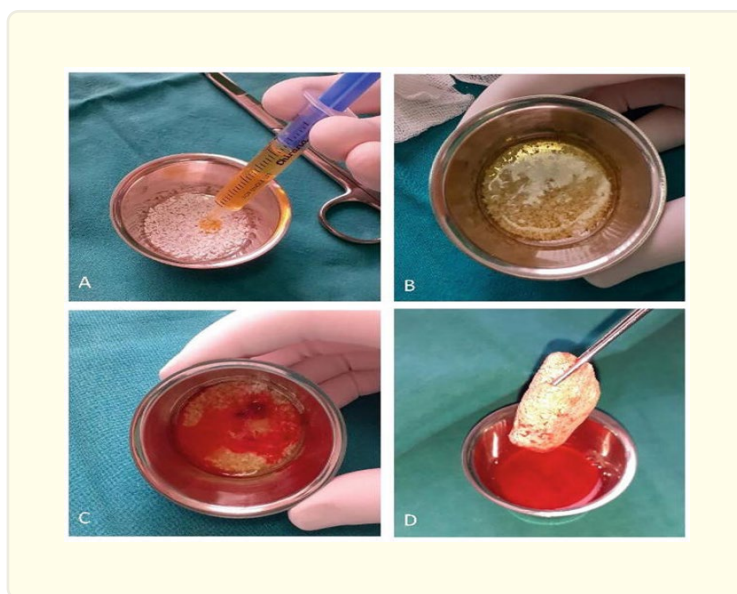
As autologous material, PRF has many advantages over other platelet concentrates, such as Platelet-rich plasma (PRP) and Plasma rich in growth factors (PRGF). Among many benefits, simple preparation (centrifugation protocol) stands out because no additional anticoagulant is added to the tubes [6]. This case report, however, sheds light on the incorporation of a novel autologous platelet concentrate-concentrated growth factor (CGF) coupled with an osseograft in surgical endodontic procedure to ensure a swift and successful recovery of the periapical region subjected to extensive lesions. The use of an osseograft combined with CGF has numerous advantages as well due to the formation of sticky bone [5].

Materials and Methods



L-PRF protocol. (A) Vacutainer with clot activator. (B) PRF clots. (C) Centrifuge with chosen protocol. (D) PRF membranes. (E) PRF plug. Blood is a liquid tissue that consists of plasma (55%), red blood cells (or erythrocytes 45%), platelets (thrombocytes), and white blood cells (leukocytes) that together account for less than 1%. In the organism, blood acts as a transporting medium, participates in coagulation, and serves as a medium for information transduction (e.g., hormones) [7].

In regenerative processes, the focus is placed on platelets. They originate from megakaryocytes in the blood marrow. Platelets are small, discoid-shaped plate-like cells that have no nucleus and have a lifespan of 8-12 days in a resting state. Apart from their role in hemostasis, they also have a role in inflammatory reactions, wound healing, host defense, and tumor biology [8].



Making sticky bone. A) Adding i-PRF into the bone substitute. B) Gel starting to form. C) Gelling completed. D) Stick bone.

Many tissues are mediated by growth factors; Epithelium and Endothelium; myocardium and neural tissue; cartilage, bone, and cementum; the more specialized connective tissue replete with extracellular matrix.

Of great help in regenerative procedures is the application of platelet concentrates that originate from the patient's blood [24]. The role of platelet concentrates in regenerative dentistry is based on the fact that they contain growth factors and scaffolds.

For this purpose, many techniques and materials have been suggested and used, but none of these systems has been totally successful, mainly due to the fact that they haven't taken advantage of the blood dynamics.

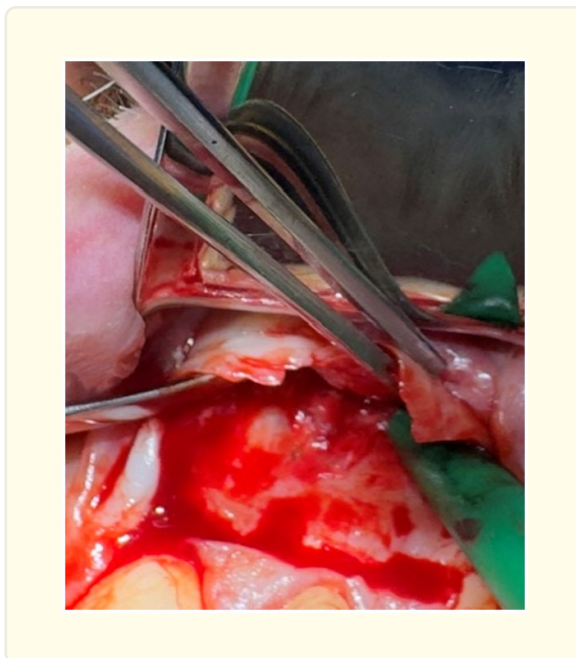
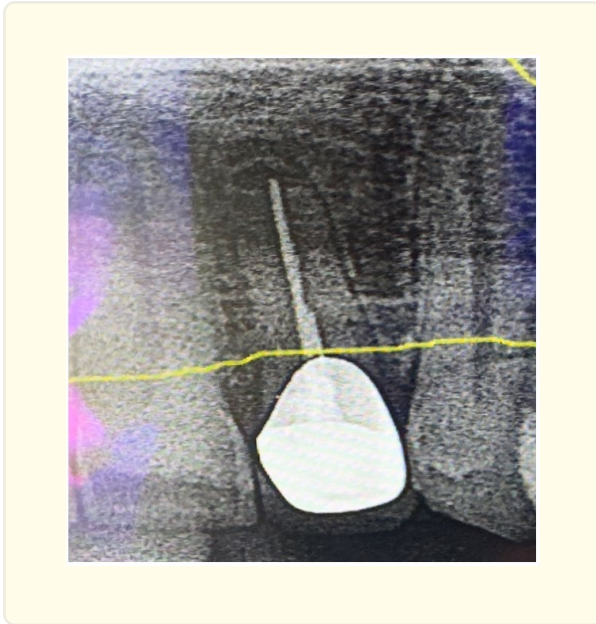
Platelet Concentrate such as Platelet Rich Plasma (PRP) has been used to accelerate tissue healing for a long time. Unlike PRP, PRF, CGF is well known to accelerate new bone formation. PRP uses complex protocols to prepare and chemical additives, concentrated growth factors (CGF) overcome these disadvantages of PRP [22].

Researchers noticed a prolonged enhancement of new bone and attachment apparatus for several weeks to months following the application of growth and differentiation factors.

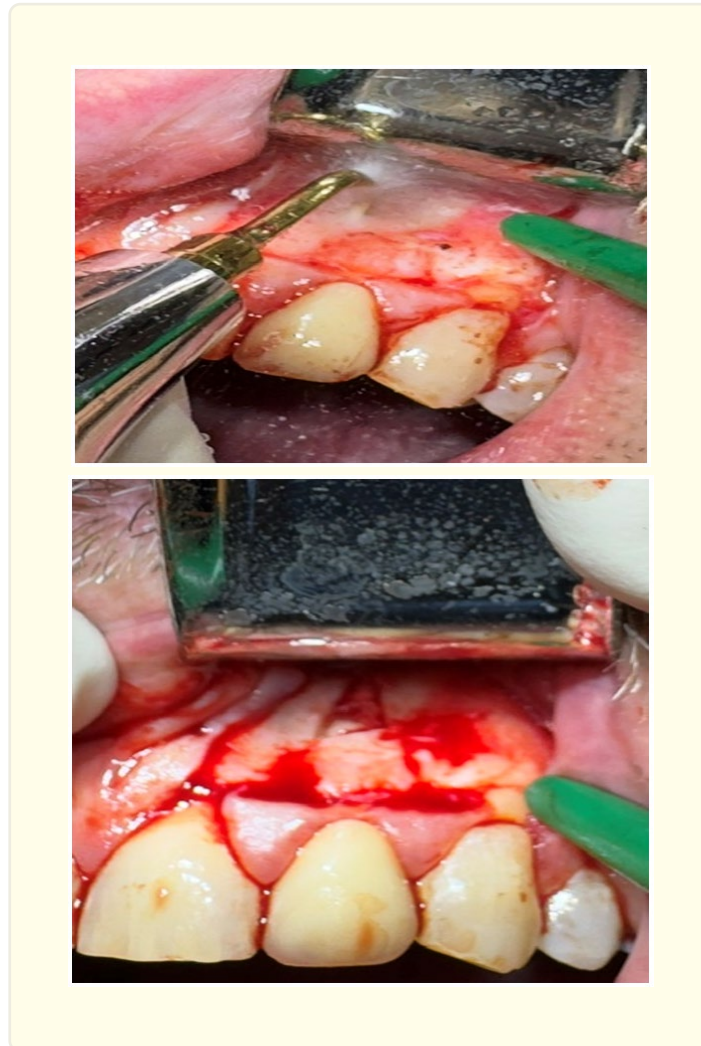
Case Report

Apicoectomy with a Cystectomy in the Maxilla

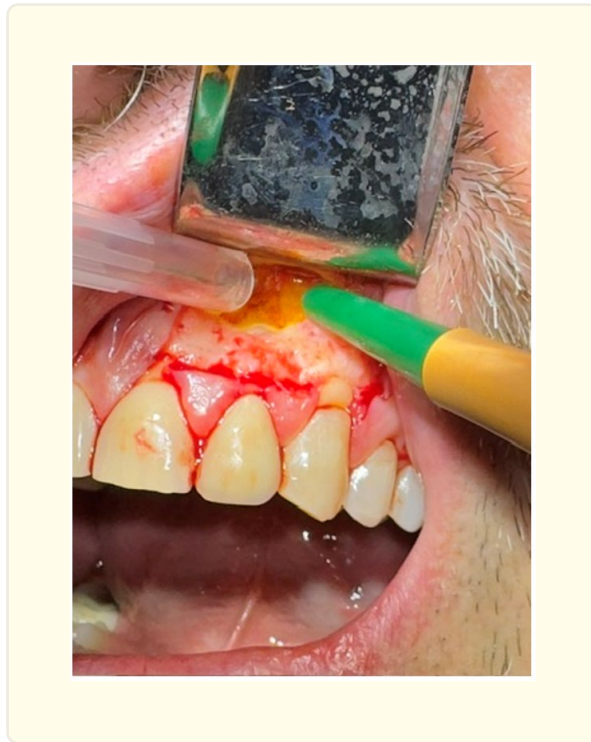
This case represents a radicular maxillary cyst encompassing tooth # (22). Patient age 40, Female, Healthy, Nonsmoker, complain of pain, swelling from time to time ends with buccal fistula, this tooth is after Root Canal treatment 12 years ago, then after a couple of years in her city they done Apicoectomy for this tooth, last year patient was referred to our clinic and The cyst has destroyed a part of the vestibular bone with its expansive growth.



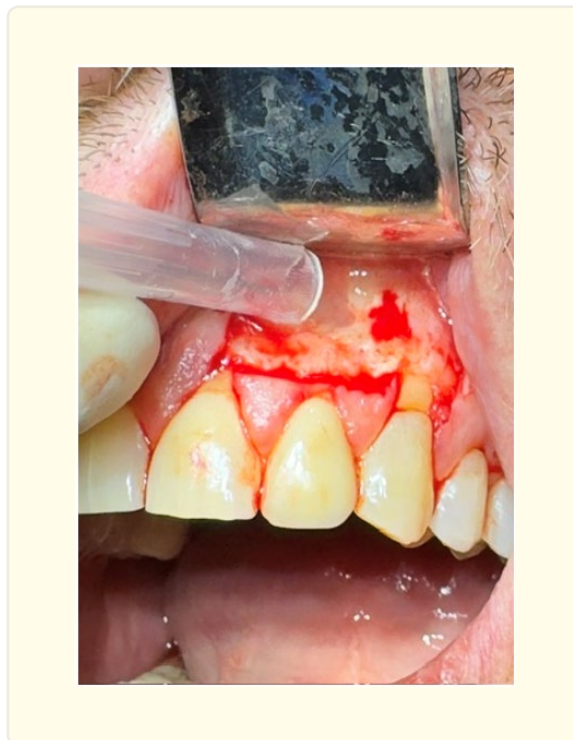Once endodontic treatment of the affected teeth had been done, apicoectomy with cystectomy was performed, with full thickness flap and free gingival attachment.



Apicoectomy and curtage as well as excavation of the radical cyst by using the Piezosurgery.

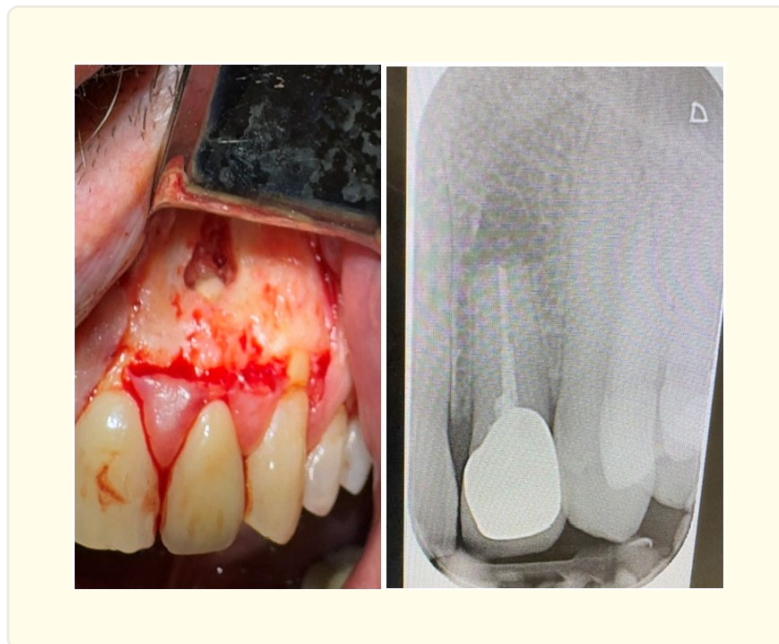

Irrigation of the operated area with Hydrogen Peroxide 3% and Betadine, for good disinfection.





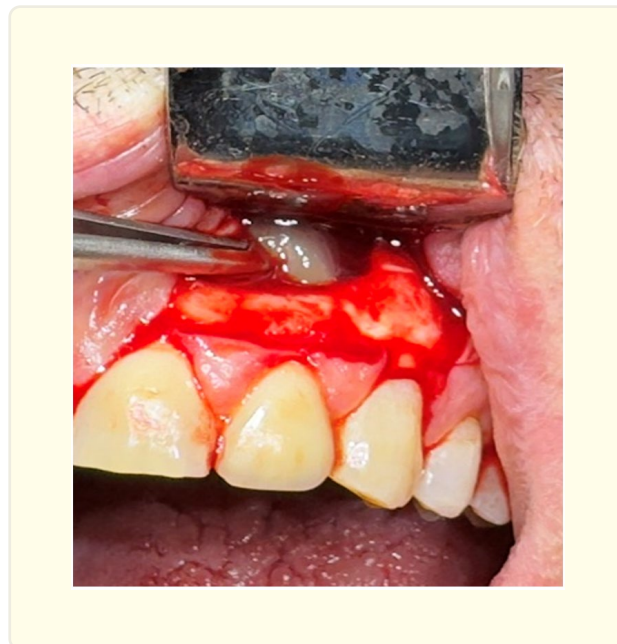
Finally, the operated area to be filled with ATB, leave it for a 2 min, then irrigate with saline ..



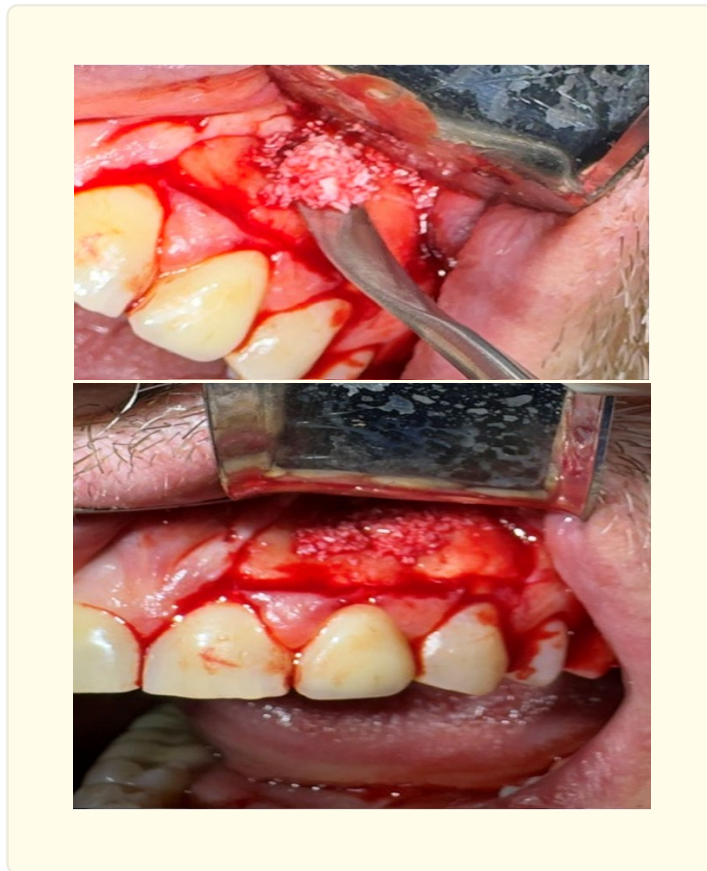Minimum Invasive surgery, with clear surgical view.PA X-ray to double check.



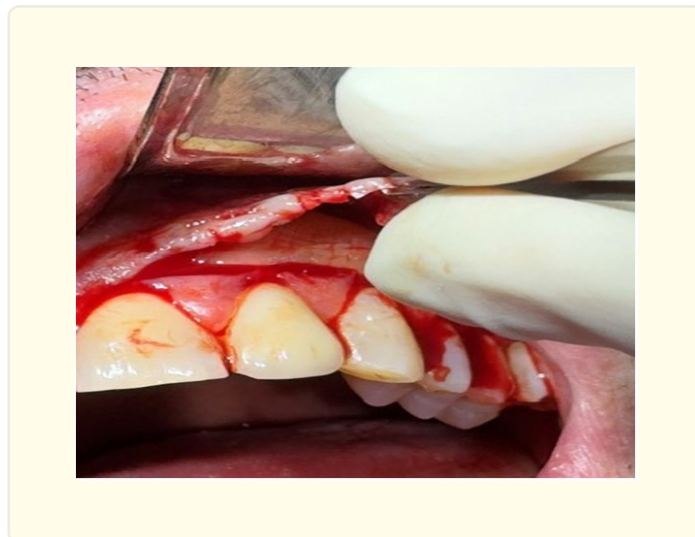A mixture of PRF membrane cut into pieces and bone substitute.

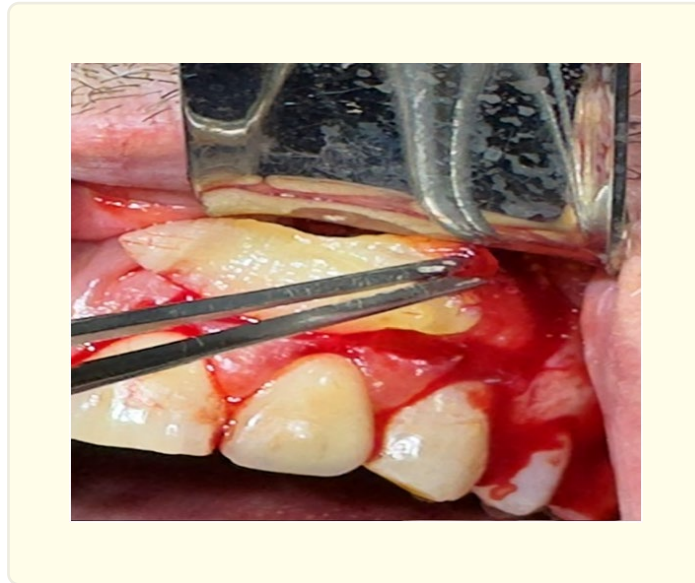


The empty alveoli were augmented by a mixture of bone graft and PRF membrane pieces PRF membranes adapted over graft.

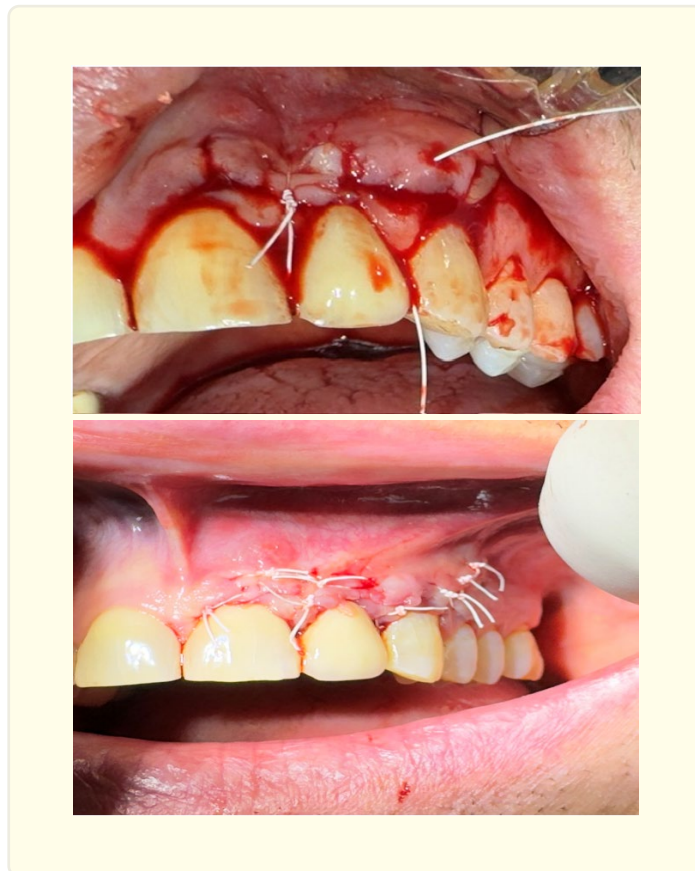


Grafting the empty alveolar socket. The bony defect was filled with a sticky bone, which was prepared with a xenograft (NeuBone).

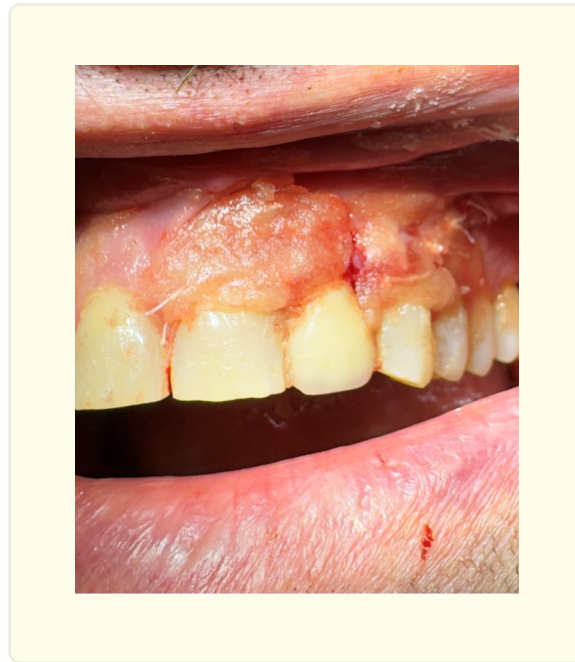



PRF membranes placed over the operating wound.

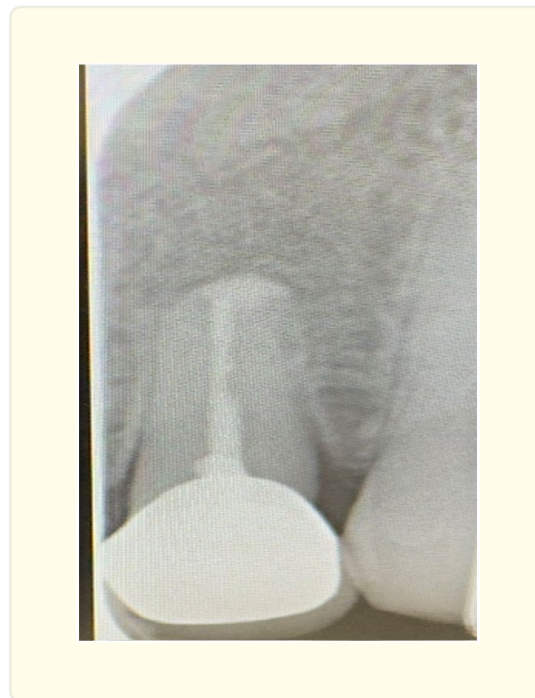


The flap was repositioned and sutured.



The flap was covered by Pac material. Sutures to be removed after 2 weeks.

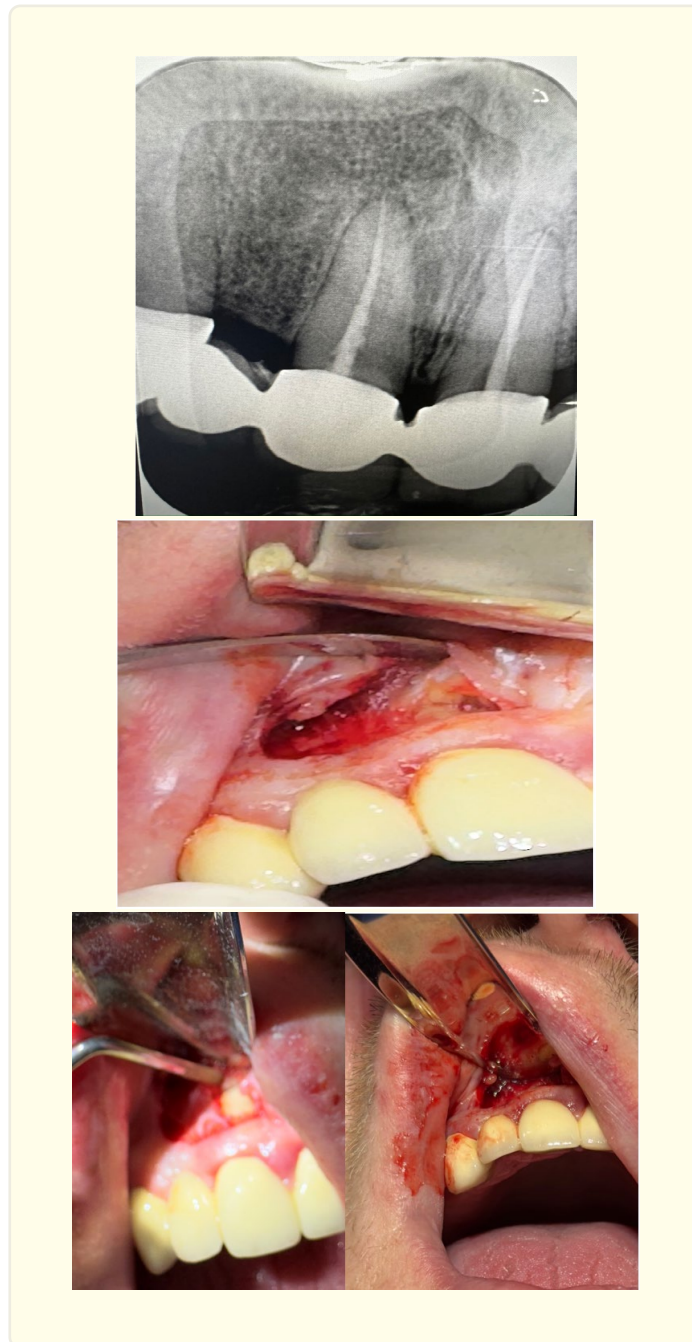
Follow-up



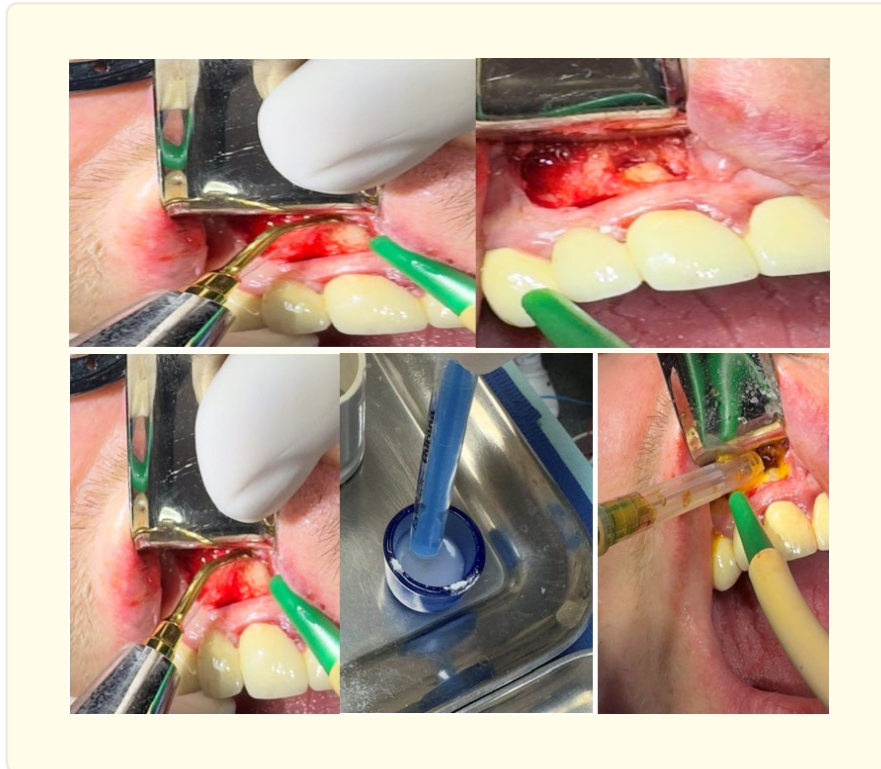
The PA control X-Ray shows excellent signs of bone regeneration after 3 months.

Second Case

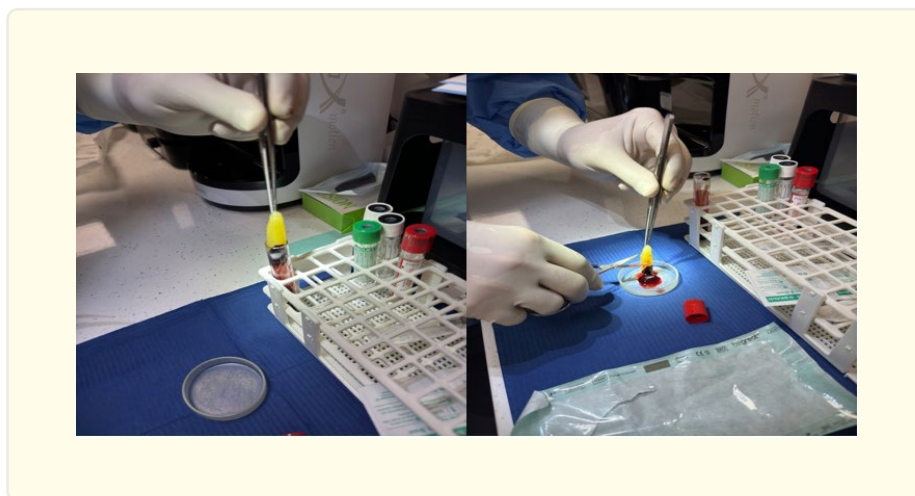
Tooth No. 11, tooth had RCT done long time ago maybe 9-10 years, Patient came to our clinic complain of pain and pressure as well as fistula buccally with discharge.

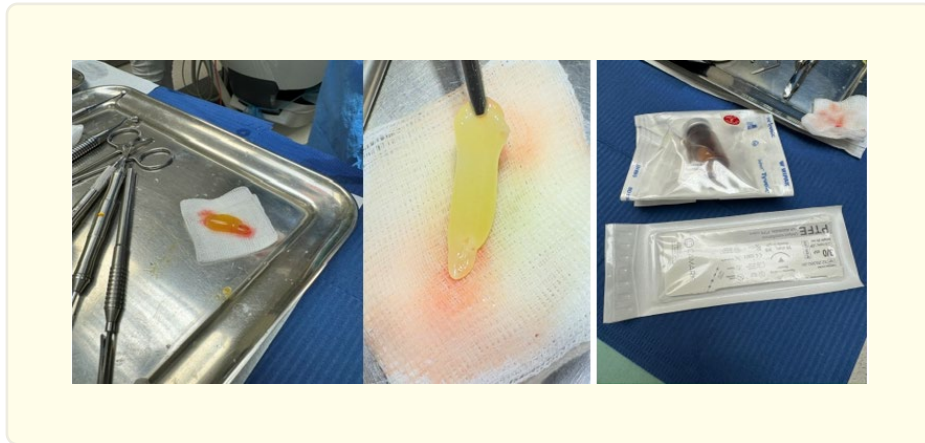


After giving Anesthesia, open flap, present huge, infected area.

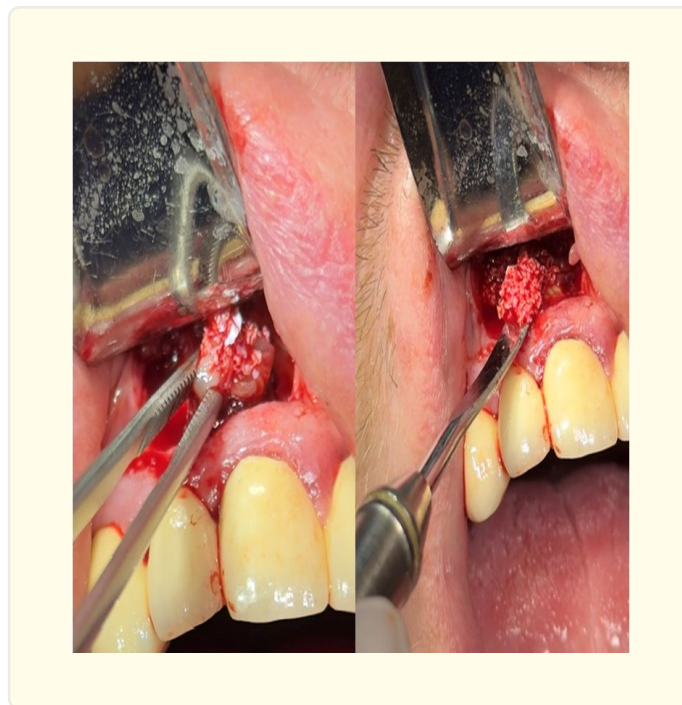

Cut the apex of the root by the Piezosurgery Unit, apply local ATB, Irrigation of the operated area with Hydrogen Peroxide 3% and Betadine, for good disinfection.

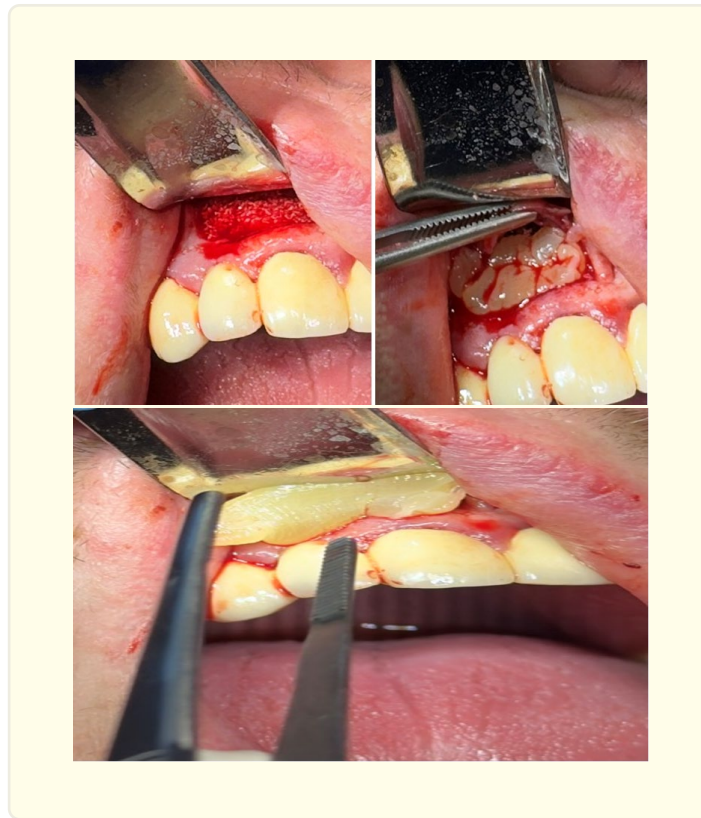




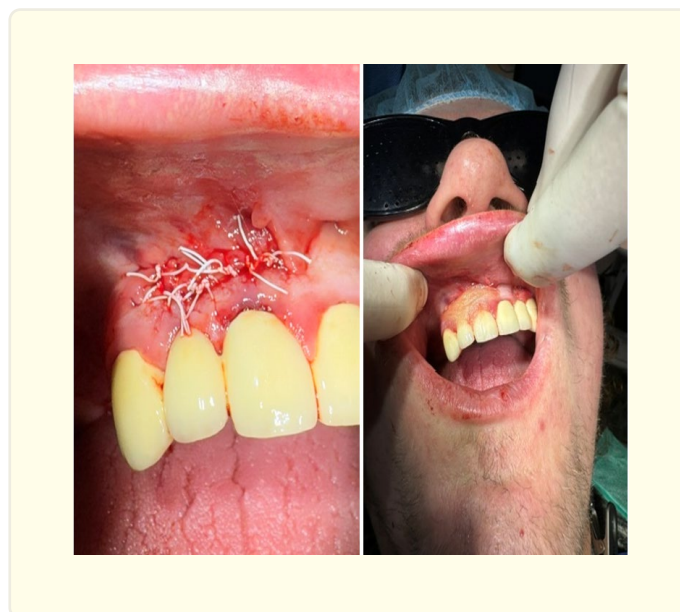PRF membrane. A mixture of PRF membrane cut into pieces and bone substitute.



Grafting the empty alveolar socket. It is a natural bone grafting material consisting of natural coral granules—98% aragonite calcium carbonate.



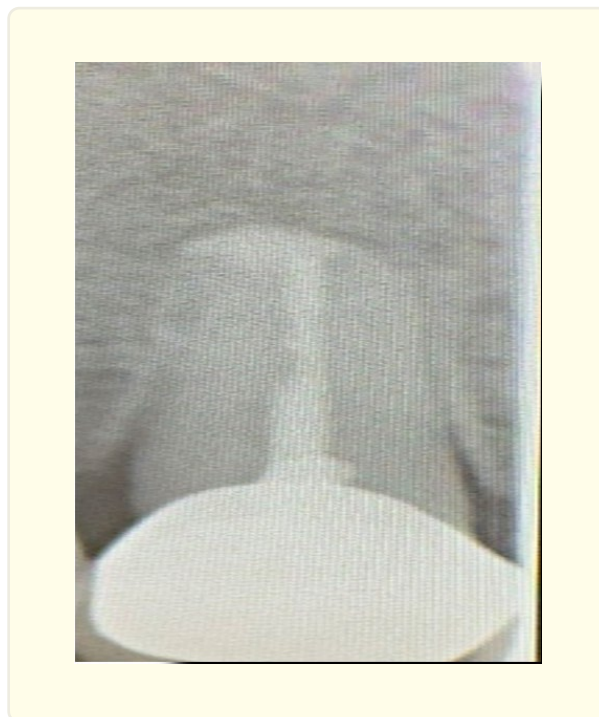
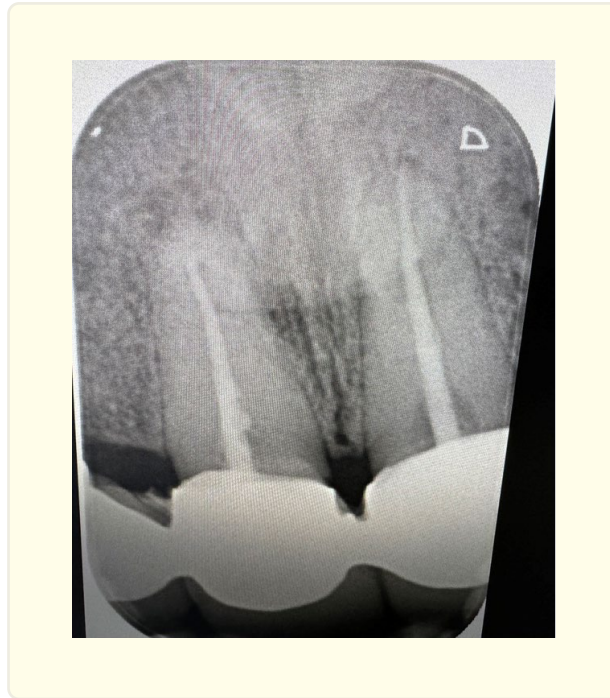The empty alveoli were augmented by a mixture of bone graft and PRF membrane pieces PRF membranes adapted over graft.



This was followed by positioning of the apical mattress stitch and a primary suturing of the elongated flap. Covered by the Pac.

Follow-up

The PA control X-Ray shows excellent signs of bone regeneration after 3 months.



Follow-up

The PA control X-Ray shows excellent signs of bone regeneration after 9 months [15].

Discussion

The present case report focuses on the use of CGF combined with bone grafts as a biomaterial that conforms to achieving repair and regeneration following periapical surgery.

CGF was prepared in a pre-programmed device, the fibrin rich blocks thus formed were larger and denser encasing innumerable growth factors [13].

Conclusion

The present case report focuses on the use of CGF combined with bone grafts as a biomaterial that conforms to achieving repair and regeneration following periapical surgery. CGF was prepared in a pre-programmed device, the fibrin rich blocks thus formed were larger and denser encasing innumerable growth factors [10].

Platelet concentrates were discovered by manipulating normal physiological processes such as hemostasis. In our previous report of two cases, CGF was effectually employed singly as a scaffolding medium, eliciting unprecedented response in terms of periapical healing. However, the present case focuses on a conspicuous coalescence of CGF and bone graft (sticky bone) to intercept a large periapical bony lesion [14].

Considering the pragmatism and relative practicality of this case in conjuncture with the available evidence on the use of sticky bone in varied specialties, CGF and bone grafts in unison can be utilized with great effect so as to yield resounding success to stem the repair and regenerative process. The present case report holds limitations on the grounds that histological evaluation of the bony defect is required to further substantiate the role of sticky bone in regeneration on a long-term basis.

Declaration of patient consent

The authors certify that they have obtained all appropriate patient consent forms. In the form the patient(s) has/have given his/her/their consent for his/her/their images and other clinical information to be reported in the journal. The patients understand that their names and initials will not be published and due efforts will be made to conceal their identity, but anonymity cannot be guaranteed.

References

1. Tabassum S and Khan FR. "Failure of endodontic treatment: The usual suspects". *Eur J Dent* 10 (2016): 144-7.
2. Nair PN, et al. "Persistent periapical radiolucencies of root-filled human teeth, failed endodontic treatments, and periapical scars". *Oral Surg Oral Med Oral Pathol Oral Radiol Endod* 87 (1999): 617-27.
3. Leuebke RG, Glick DH and Ingle JI. "Indications and contraindications for endodontic surgery". *Oral Surg Oral Med Oral Pathol* 18 (1964): 97-113.
4. Vaishnavi C, Mohan B and Narayanan LL. "Treatment of endodontically induced periapical lesions using hydroxyapatite, platelet-rich plasma, and a combination of both: An in vivo study". *J Conserv Dent* 14 (2011): 140-6.
5. Dohan DM, et al. "Platelet-rich fibrin (PRF): A second-generation platelet concentrate. Part I: technological concepts and evolution". *Oral Surg Oral Med Oral Pathol Oral Radiol Endod* 101 (2006): e37-44.
6. Borsani E, et al. "Biological characterization and in vitro effects of human concentrated growth factor preparation: An innovative approach to tissue regeneration". *Biol Medicine* 7 (2015): 1.
7. Sohn DS, et al. "The use of concentrated growth factors (CGF) for sinus augmentation". *J Oral Implant* 38 (2009): 25-38.
8. Mellonig JT. "Autogenous and allogeneic bone grafts in periodontal therapy". *Crit Rev Oral Biol Med* 3 (1992): 333-52.

9. Doan N, et al. "A review on the application of concentrated growth factors and MPhi laser to regenerate oral defects in the oral and maxillofacial region and a two cases report". *Int J Oral Maxillofac Surg* 46 (2017): 203-4.
10. Rodella LF, et al. "Growth factors, CD34 positive cells, and fibrin network analysis in concentrated growth factors fraction". *Microsc Res Tech* 74 (2011): 772-7.
11. Gosiewska A., et al. "Characterization of a macrophage-based system for studying the activation of latent TGF-beta". *Methods Cell Sci* 21 (1999): 47-56.
12. Lakey MA, Klein MJ and Faye-Petersen OM. "A comprehensive clinicopathologic analysis suggests that vascular endothelial growth factor (VEGF) is the most likely mediator of periosteal new bone formation (PNBF) Associated with diverse etiologies". *Clin Med Arthrit Musculoskeletal Disorders* 1 (2008): CMAMD-S442.
13. Park HC., et al. "Early bone formation at a femur defect using CGF and PRF grafts in adult dogs: A comparative study". *Implant Dent* 25 (2016): 387-93.
14. Estrela C., et al. "Accuracy of cone beam computed tomography and panoramic and periapical radiography for detection of apical periodontitis". *J Endod* 34 (2008): 273-9.
15. Fayad MI., et al. "AAE and AAOMR joint position statement: Use of cone beam computed tomography in endodontics 2015 update". *Oral Surg Oral Med Oral Pathol Oral Radiol* 120 (2015): 508-12.
16. Costello BJ., et al. "Regenerative medicine for craniomaxillofacial surgery". *Oral and Maxillofacial Surgery Clinics of North America* 22 (2010): 33-42.
17. Miron RJ., et al. "Use of platelet-rich fibrin in regenerative dentistry: A systematic review". *Clinical Oral Investigations* 21 (2017): 1913-1927.
18. Dean L. "Blood and the cells it contains". National Center for Biotechnology Information (NCBI). National Library of Medicine. Bethesda, USA: National Institutes of Health (2005).
19. Holinstat M. "Normal platelet function". *Cancer Metastasis Reviews* 36 (2017): 195-198.
20. Blair P and Flaumenhaft R. "Platelet α -granules: Basic biology and clinical correlates". *Blood Reviews* 23 (2009): 177-189.
21. Prakash S and Thakur A. "Platelet concentrates: Past, present and future". *Journal of Maxillofacial Oral Surgery* 10 (2011): 45-49.
22. Coppinger J and Maguire P. "Insights into the platelet releasate". *Current Pharmaceutical Design* 13 (2007): 2640-2646.
23. Chou TM, Chang HP and Wang JC. "Autologous platelet concentrates in maxillofacial regenerative therapy". *The Kaohsiung Journal of Medical Sciences* 36 (2020): 305-310.
24. Caruana A., et al. "From platelet-rich plasma to advanced platelet-rich fibrin: Biological achievements and clinical advances in modern surgery". *European Journal of Dental* 13 (2019): 280-286.
25. Dohan Ehrenfest D., et al. "In search of a consensus terminology in the field of platelet concentrates for surgical use: Platelet-rich plasma (PRP), platelet-rich fibrin (PRF), fibrin gel polymerization and leukocytes". *Current Pharmaceutical Biotechnology* 13 (2012): 1131-1137.

Volume 6 Issue 4 April 2024

© All rights are reserved by Alaa Abu Shareia., et al.