Medicon Dental Sciences
Volume 4 Issue 1 January 2024
Article Type: Case Report
ISSN: 3008-2609

Proliferative Periostitis of Garre: Report of a Case Managed by Endodontic Treatment

Emna Garouachi[1], Amira Kikly[2], Neila Zokkar[3] and Nabiha Douki[3]*

[1]DDS, Department of Dentistry, university hospital, Sahloul, Faculty of Dental Medicine, University of Monastir, Research Laboratory LR12ES11, Tunisia

[2]DDS, Associate professor, Department of Dentistry, university hospital, Faculty of Dental Medicine, University of Monastir, Research Laboratory LR12ES11, Tunisia

[3]DDS, Professor, Department of Dentistry, university hospital, Faculty of Dental Medicine, University of Monastir, Research Laboratory LR12ES11, Tunisia

***Corresponding Author:** Nabiha Douki, DDS, Professor, Department of Dentistry, university hospital, Faculty of Dental Medicine, University of Monastir, Research Laboratory LR12ES11, Tunisia.

Received: December 11, 2023; **Published:** December 30, 2023

Abstract

The term "osteomyelitis" refers to infection of the bone marrow; the term "osteitis" describes involvement of the entire organ including the bone cortex. The most common provoking factors in the jaw region are a previous tooth extraction, tooth eruption, dental caries with associated periapical inflammation, periodontal infections, untreated fractures and non-odontogenic infections. Endodontic therapy, tooth extraction, and bone recontouring are all alternatives for treatment, ranging from conservative to surgical procedures. In the past, antibiotics and removal of the offending tooth followed by curettage of its socket were commonly used to treat Garre's osteomyelitis. Endodontic therapy, on the other hand, has been reported as a successful method of treating odontogenic causes of Garre's osteomyelitis.

In this article we aimed to present the clinical and radiographic findings and to discuss the endodontic treatment option for a young patient diagnosed with Garre's osteomyelitis.

Keywords: Garre's osteomyelitis; Periostitis; Endodontic therapy; calcium hydroxide irrigation

Introduction

Garre's osteomyelitis is named after Carl Garre, who first observed the condition in the tibia in 1893 and described it as "a focal gross thickening of periosteum with peripheral reactive bone formation resulting from infection". Pell and al were the first to describe a case of proliferative periostitis affecting the jaw bones [1, 2]. Several connotations have been adopted for this entity include proliferative periostitis of Garre, Garre's osteomyelitis, periostitis ossificans (PO), nonsuppurative ossifying periostitis, osteomyelitis sicca, osteomyelitis with proliferative periostitis and perimandibular ossification [1].

It is a specific type of chronic osteomyelitis that commonly occurs in young patients [2, 3]. In 80% of cases, the age at disease onset was under 14 years old. There was a slight predominance of males, with a female to male ratio of 1/1.4 [4].

The mandible is more affected than the maxilla and the most common site of involvement is the inferior border of the mandible in the first molar region [1, 2].

The most provoking factors in the jaw region are previous tooth extraction, tooth eruption, dental caries with associated periapical inflammation, periodontal infections, fractures and non-odontogenic infections [5].

Clinically, patients may present with a hard swelling of the jaw and facial asymmetry caused by this reactive process [3].

The radiographic appearance varies with the duration of the lesion and the degree of calcification. In the initial stages, a delicate, crust-like convex layer emerges on the cortex. As the process advances, the cortex undergoes thickening due to successive deposition of new bone [6]. This lamellar arragement is commonly identified as "onion skin" on radiographs [1, 2, 6]. Periapical, occlusal and panoramic radiographs are often used for diagnosis of periostitis ossificans and have a high diagnostic value. Computed tomography may also be used and it is accurate for detecting not only typical alterations inside the bone, but also periosteal reactions and soft tissue involvement. The treatment usually involves the extraction of the affected tooth, which leads to occlusal alterations and can impact on the quality of life of the patient. Few studies indicated less invasive alternatives.

In this article we intended to showcase the clinical and radiographic findings and to discuss the endodontic treatment option for a young patient diagnosed with Garre's osteomyelitis.

Case report

An 11-year-old boy presented to our department with a 3-month history of painless swelling on the left side of the mandible. The patient underwent antibiotic treatment (Augmentin), but as it proved ineffective, he was subsequently referred to our department.

- Extraoral examination revealed a diffuse nontender bony hard swelling of size approximately 2*2cm on the inferior aspect of left body of mandible (Figure 1). The patient's skin exhibited a normal coloration and appearance and there was no pain on palpation of the swelling. There was no lymphadenopathy, and the patient was afebrile. Mouth opening was normal.
- Intraoral examination revealed a Sista 2.3 classified carious lesion of the left mandibular first molar. The tooth did not respond positively to the vertical/horizontal percussion or thermal tests. There was an absence of any sinus tract, but a fixed indurated swelling presented on buccal vestibule of tooth (Figure 2).
- The panoramic and periapical radiographs indicated the presence of a deep caries cavity and a radiolucent area in the apical region associated with both mesial and distal roots of the left mandibular first molar (Figure 3,4).
- Mandibular occlusal radiograph showed an expansion of periosteum extending 0.5cm buccally to the first molar with the presence of about three parallel lamellae giving an onion-skin appearance (Figure 5).

  When all these findings were evaluated, we determined that the primary diagnosis of this pathologic lesion was Garre's osteomyelitis, resulting from periapical infection of the left mandibular first molar, and the differential diagnosis was Ewing sarcoma at its initial stage.

In the present case report, endodontic treatment was the treatment of choice due to the patients' young age, the possibility of maintaining the tooth and the positive attitude of the patients and their parents toward this treatment plan.

In the first appointment, the caries was eradicated, and the access cavity preparation revealed necrotic pulp with no apparent odor or purulence present. The root canal was irrigated between instrumentation with 2.5% sodium hypochlorite and for one to two minutes after completing the instrumentation. Ethylenediaminetetraacetic acid (EDTA) 17% was then used as the final irrigant for around two minutes to complete the removal of the smear layer. Afterwards a 2% CHX solution was used as we know its ability to bind to hard tissue and remains antimicrobial (substantivity).

The canal was then dried, calcium hydroxide was placed in the canal, and an interim restoration was placed.

Two weeks later, there was a reduction in the swelling on the right side of the mandible. Intracanal medicament was changed and followed by the interim restoration. On the next and last visit, extraoral examination showed a disappearance of the swelling (Figure 6).

The endodontic treatment was then completed using gutta percha for the root filling and zinc oxide eugenol as a sealer.

The patient was called for clinical and radiographic follow-up visits after 2, 4, 6 ,8 and 12 months.

At the 4-month follow-up, the patient was asymptomatic with no visible or palpable swelling. There was no discomfort in percussion or palpation, and mobility was normal. A periapical radiograph showed periapical lesion regression (Figure 7(a)). Occlusal radiograph showed resolution of the proliferative bone (Figure7(b)).

At the 8-month follow-up, a periapical radiograph revealed a notable regression of the periapical radiolucency associated with the mesial root and a complete disappearance of periapical radiolucency in connection with the distal root. (Figure 8)

By the 12-month follow-up, the periapical radiograph demonstrated complete bone healing with the total disappearance of periapical radiolucency. (Figure 9)

Figure 1: Extraoral view shows a noticeable bony swelling at the lower border of the left side of the mandible with facial asymmetry.

Figure 2: Intraoral view showing a deep caries in the first left mandibular molar.

Figure 3: Periapical radiograph revealing a well-defined radiolucent lesion associated with both the mesial and distal roots of the left mandibular first molar.

Figure 4: A cropped panoramic radiograph revealed a penetrating caries with periapical radiolucency and the cortex of the mandible appears intact.

Figure 5: A mandibular occlusal view showing the onion skin pattern of periosteal expansion noted opposite to the left mandibular first molar.

Figure 6: 1 month follow-up after the endodontic treatment: clinical healing with resolution of the extraoral swelling.

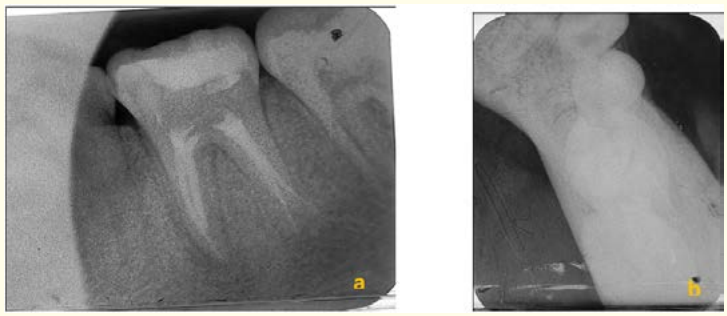

Figure 7: At 4-month follow-up: (a)Periapical radiographic control showing periapical lesion regression. (b) Occlusal radiograph showing healing of the periosteal reaction.

Figure 8: At 8-month follow-up: the periapical radiograph showing a significant regression, of the initial periapical lesion size, in relation to the mesial root of the tooth and complete disappearance of periapical radiolucency in relation to the distal root.

Figure 9: One year follow-up: the periapical radiograph showing complete healing of the periapical lesion in relation to both mesial and distal roots.

Discussion

The term "osteomyelitis" denotes an infection of the bone marrow, while "osteitis" encompasses the involvement of the entire organ, including the bone cortex. In the Anglo-American context, "osteomyelitis" is the preferred term and is interchangeably used to describe both conditions.

Garre's osteomyelitis is a distinctive type of chronic osteomyelitis associated with gross thickening of the periosteum of the bones and peripheral reactive bone formation generally originates from an infection of low virulence. This condition commonly occurs in young patients with a main age of 13 years.

Ethiopatogeny

The most prevalent provoking factors in the jaw region include a history of tooth extraction, tooth eruption, dental caries accompanied by periapical inflammation, periodontal infections, untreated fractures and non-odontogenic infections [2]. Most cases arise in the molar/premolar area of the mandible. In our case the causative agent was pulp necrosis of the lower first molar coupled with a chronic periapical infection. The progression of the infection from the spongiosa layer of the jaw into the periosteum stimulates bone formation. Nevertheless, for this pathological condition to manifest, there must be an imbalance between virulent bacteria and oral flora, and simultaneously, there should be heightened periosteal osteoblastic activity [6].

Diagnosis

Facial asymmetry, the presence of complaint and pain are not characteristic findings. The other markers of inflammation like fever, white blood cells count and c-reactive protein may not elevate characteristically.

This disease process initiates in the spongy bone and extends into the periosteum, leading to an osteoblastic reaction. Unfortunately, in certain cases, the disease may progress further into the perimandibular soft tissue, leading to the formation of abscesses and fistulas. In such cases, severe trismus can occur, indicating masticator space infection [7].

Our patient visited our department with the presenting complaint of swelling on the right side of the mandible for 3 months. On extraoral examination, it was found that a diffuse non-tender swelling was present on the right side of the mandible. The swelling was

hard and painless on palpation. The overlying skin color was normal and no lymphadenopathy was present.

The intraoral examination identified a firm swelling at the base of the vestibule associated with the first mandibular molar. The mucosa appeared erythematous.

The lesion is usually asymptomatic with no accompanying general and local signs of inflammation, although the clinical picture may vary widely. Therefore, attention should be directed towards objective symptoms not associated with signs of malignancy, such as dental mobility, hypoesthesia, dental displacement, and severe trismus [8].

In addition to Garre's osteomyelitis, new bone formation can occur in various pathological conditions. Therefore, it is crucial to differentiate it from other pathologies leading to new bone formation, such as Ewing's sarcoma, osteosarcoma, and fibrous dysplasia, which typically manifests at younger ages, resembling Garre's osteomyelitis in both shape and volume of the resulting bone mass [3]. For this reason, radiographic examinations were essential to confirm the accurate diagnosis.

Conventional radiographs including panoramic and periapical radiography, can help confirm the etiopathology by showing a chronic tooth infection, a periapical radiolucency, bone loss, marginal cyst, or changes at an extraction site. In the current case, both panoramic and periapical radiographs revealed a penetration carious lesion in the left mandibular first molar with a well-defined radiolucent periapical image in relation to both the mesial and distal roots of the tooth.

As for the occlusal radiography in our case, revealed the presence of radiopaque bone laminations (about 3 layers) that are parallel not only to each other but also to the underlying cortical bone. The presence of these laminations suggests a typical radiographic feature such as an "onion skin" appearance [1, 5, 9].

Intraoral periapical, occlusal, and panoramic radiographs are often used for preliminary diagnosis [9]. In cases when conventional radiographs could not be able to detect any change at the inferior border of the mandibular body especially in the first stage of the evolvement of periostitis ossificans, when no radiologic evidence of bone formation can be present, computed tomographs (CT) may be useful to confirm the diagnosis and investigate the lesion in greater detail [10]. In fact, Periosteal new bone formation in mandibular osteomyelitis may not be visualized on conventional radiographs until 1 month has elapsed after infection [11].

In our case the clinical findings along with the radiographic features which were characteristic of PO, with successive layers of bone deposition recognized as the "onion skin" appearance clearly seen in the occlusal radiography, were sufficient to confirm the right diagnosis and CT scanning was not performed.

This last one is also helpful in identifying the extent of bone involvement and its relationship with the adjacent anatomical structures [9].

Differential diagnosis

The differential diagnoses of yet to diagnose PO includes malignant and benign entities causing bone formation and may have the same radiographic appearance. This includes Ewing's sarcoma, Caffey disease, fibrous dysplasia, Paget's disease, osteosarcoma, and hard, nodular, or pedunculated masses seen in the mandible (peripheral osteomas, torus and exostoses, ossifying subperiosteal hematoma, etc.) [6].

1. Caffey disease and Garre's osteomyelitis share the same "onion skin" appearance in the bone. However, Caffey disease can be differentiated by its early onset (before two years of age) and a higher prevalence in the ramus and angulus region of the mandible, displaying bilateral involvement and affecting multiple bones [6].
2. 2.Ewing's sarcoma and Osteosarcoma both can produce a hard bone mass on the bone surface and appear in young people which is similar to Garre's osteomyelitis. However, they can be differentiated from Garre's osteomyelitis, due to the occurrence of frequent complications because of their malignant aspect, such as facial neuralgia and lip paresthesia as well as the radiological

feature with a "sun-ray" appearance [6].

3. Fibrous dysplasia is another pathological condition that requires a differential diagnosis. It occurs in younger ages and cause a bone mass formation similar in shape and volume to the one resulting from Garre's periostitis. But, unlike periostitis ossificans it is not consequent to dental infection. Radiographically, both conditions can produce images characterized by regions of sclerosis with and without osteolytic areas and jaw. Yet, the increase in volume in cases of PO is due to new bone formation in the periosteum, whereas the increase in fibrous dysplasia is the result of support bone formation on the outer side of the cortex secondary to remodeling stemming from endosteal erosion and appears with a "ground glass" aspect [5, 6].

Treatment

Endodontic therapy, tooth extraction, and bone recontouring are all alternatives for treatment, ranging from conservative to surgical procedures. In the past, antibiotics and removal of the tooth followed by curettage of its socket were commonly used to treat Garre's osteomyelitis. Endodontic therapy, on the other hand, has been reported as a successful method of treating odontogenic causes of Garre's osteomyelitis [13].

A review of the literature on chronic-non suppurative osteomyelitis with proliferative periostitis cases of the jaw showed that 35,5 % of cases have been successfully treated using a conservative endodontic treatment, which was associated in half of the cases with antibiotic therapy [12].

In our present case we considered the endodontic therapy since the tooth was restorable, the young age of the patient and the favorable attitude of the patient and his parents regarding this treatment plan.

The treatment plan adopted in our case was focused on local control of dental infection through endodontic treatment. Local response to the control of dental infection is a key guiding to the success of the treatment and this includes reduction of mandibular expansion and the resolution of the jaw swelling [14].

To enhance the success rate of endodontic treatment, particularly for necrotic teeth, we should put more focus on the chemo-mechanical preparation.

In fact, Instrumentation and irrigation are the most important parts of root canal treatment as they fulfill several important mechanical, chemical and (micro) biological functions leading to periapical healing. Emphasizing special attention to endodontic irrigation is crucial, as it represents the unique method to reach areas of the root canal wall untouched by mechanical instrumentation. These areas harbor tissue remnants and biofilms, necessitating chemical removal through irrigation. In clinical application, the use of a specific sequence of solutions is essential to optimize the contribution to the success of root canal treatment [15].

In our present case, we used calcium hydroxide as an inter-appointment medication and as a supplement to antibacterial irrigations to optimize the disinfection of the root canal before obturation.

Previous studies have shown that cleaning and shaping of the root canal system with conventional chemo-mechanical methods can only eliminate half of the bacterial population of root canal. Therefore, antibacterial intracanal medication has been advocated to eliminate remaining bacteria after canal instrumentation and irrigation [16]. However, other studies have suggested that the additional disinfecting effect of intracanal calcium hydroxide used in multi-visit treatment cannot be overstressed and have found that a complete disinfection of the canal is not possible and that a bacterial recolonization occurred at the levels similar to what was before the instrumentation of the canal [16]. Furthermore, some bacteria species, such as E. faecalis and Candida albicans, have been identified as resistant to it [17].

Sjogren et al. reported a higher success rate in terms of periapical healing (94%) when a negative culture was present prior to obturation, compared to cases with a positive culture (68%) [17]. Therefore, whether we opted for single or multiple visit treatment approaches, it is crucial for the clinician to adhere closely to endodontic principles. There should be no shortcuts in any of the steps

throughout the treatment procedures to ensure substantial disinfection before root canal obturation.

Concerning the use of antibiotics, they have been frequently employed, but their usefulness in treating this disorder is yet to be confirmed.

Antibiotic therapy alone is ineffective, independent of the administration route, because the "bone sequestration" found in the chronic disease comprises fragments of necrotic bone and thus does not present a blood supply that would allow antibiotic to arrive at the infected tissue [3].

In fact, the indications for adjunctive antimicrobial treatment include fever of greater than 100°F, malaise, lymphadenopathy, trismus, cellulitis, and rapid swelling of the soft tissue associated with infection. Therefore, antibiotic therapy was not indicated in our reported case since none of these symptoms were present [18]. This case demonstrates that proliferative periostitis of Garre can be treated with conventional endodontic therapy without the need for antibiotic therapy.

Evolution and follow-up

In our case, an early response rate was used as a guide to follow-up, making the assumption that successful endodontic therapy would be an effective option in breaking the pathogenic sequence.

A positive clinical response was observed in the weeks after endodontic treatment and the jaw swelling has been observed to begin a gradual process of resolution.

Periosteal reaction healing was observed at 4 months. 11 months post treatment periapical radiography revealed signs of mandibular bone regeneration and resolution of periapical radiolucency.

A long-term follow-up should be carried when endodontic treatment is performed, because the lesion may continue to increase in size after apparently successful treatment, then a biopsy should be indicated [19]. In our case biopsy was not performed as a favorable response has been seen all along our follow-up period and the cause of infection was obvious. For these same reasons, no surgical intervention was needed.

In fact, if a carious tooth is not present, a search for other irritation or etiologic agents should be performed. A biopsy would then be essential for a histopathological diagnosis [18]. In such cases, with unknown etiology, the treatment varied from prescribing antibiotics to surgical procedures: removal of the newly formed bone, curettage of the lesion or remodeling osteoplasty [12, 18].

Conclusion

The Garre's osteomyelitis is a well-described pathologic entity. It is rare in occurrence because its development depends on the occurrence of a set of critically integrated conditions; that is chronic infection in a young individual, with a periosteum capable of vigorous osteoblastic activity and equilibrium between the virulence of the infectious agents and the resistance of the host.

Radiographic examinations are important diagnostic and monitoring tools of this pathology, especially in aggressive and atypical forms other than the most frequent "onion skin" type. Conservative treatment, by performing an endodontic therapy, should be considered as the main treatment goal as is it demonstrated to be successful in our present case.

References

1. Gumber, P., et al. "Garre's sclerosing osteomyelitis-A case report". Journal of Advanced Medical and Dental Sciences Research 4.2 (2016): 78.
2. George S and Girija KL. "Garres Osteomyelitis: A Case Repor". Kerala Dental Journal (2016).
3. Aeran H., et al. "Management of Garré's sclerosing osteomyelitis by endodontic therapy: A case report". International Journal of

Oral Health Dentistry (2021).

4. Shah KM, Karagir A and Adaki S. "Chronic non-suppurative osteomyelitis with proliferative periostitis or Garre's osteomyelitis". Case Reports (2013): bcr2013009859.
5. Chang YC., et al. "Chronic osteomyelitis with proliferative periostitis in the lower jaw". Journal of Dental Sciences 10.4 (2015): 450-455.
6. Akgül HM., et al. "Garre's osteomyelitis of the mandible caused by infected tooth". Case Reports in Dentistry (2018).
7. Shanmuga Jayanthan S and Ganesh R. "Garré's Sclerosing Osteomyelitis with Perimandibular Soft Tissue Inflammation and Fistula". Indian J Radiol Imaging (2022).
8. Bougatef H., et al. "Periostitis Ossificans: Report of Two Cases Resolved with Endodontic Treatment". Case Reports in Dentistry (2020).
9. Passi S., et al. "Diagnostic Challenge Involving Diffuse Mandibular Swelling in Mixed Dentition: Use of Cone-beam Radiography". International Journal of Clinical Pediatric Dentistry 14.3 (2021): 430.
10. Nortje CJ, Wood RE and Grotepass F. "Periostitis ossificans versus Garrè's osteomyelitis: Part II: Radiologic analysis of 93 cases in the jaws". Oral surgery, oral medicine, oral pathology 66.2 (1988): 249-260.
11. Kawai T., et al. "Radiographic investigation of mandibular periostitis ossificans in 55 cases". Oral Surgery, Oral Medicine, Oral Pathology, Oral Radiology, and Endodontology 82.6 (1996): 704-712.
12. Taihi I and Radoi L. "Chronic non-suppurative mandibular osteomyelitis with proliferative periostitis: A review". Quintessence Int 49.3 (2018): 219-26.
13. Alexander A, Saravanakumar MS and Joy A. "Garre's Osteomyelitis from Long Standing Periapical Infection of 36 in a 10yr old Female-A Case Report". Oral and Maxillofacial Pathology Journal 13.1 (2022).
14. Mattison GD., et al. "Garre's osteomyelitis of the mandible: the role of endodontic therapy in patient management". Journal of Endodontics, 7(12), (1981) 559-564.
15. Haapasalo M., et al. "Irrigation in endodontics". British dental journal 216.6 (2014): 299-303.
16. Akbar I, Iqbal A and Al-Omiri MK. "Flare-up rate in molars with periapical radiolucency in one-visit vs two-visit endodontic treatment". The journal of contemporary dental practice 14.3 (2013): 414.
17. Wong AW, Zhang C and Chu CH. "A systematic review of nonsurgical single-visit versus multiple-visit endodontic treatment". Clinical, cosmetic and investigational dentistry 6 (2014): 45.
18. Zand V, Lotfi M and Vosoughhosseini S. "Proliferative periostitis: a case report". Journal of Endodontics 34.4 (2008): 481-483.
19. Ebihara A, Yoshioka T and Suda H. "Garre's osteomyelitis managed by root canal treatment of a mandibular second molar: incorporation of computed tomography with 3D reconstruction in the diagnosis and monitoring of the disease". International Endodontic Journal 38.4 (2005): 255-261.

Volume 4 Issue 1 January 2024